


Handheld fundus camera performance, image quality and outcomes of diabetic retinopathy grading in a pilot screening study

Anna-Maria Kubin,^{1,2,3} Joonas Wirkkala,^{1,2,3} Antti Keskitalo,^{2,3} Pasi Ohtonen³ and Nina Hautala^{1,2,3} 

¹Department of Ophthalmology, PEDEGO Research Unit and Medical Research Center, Oulu University, Oulu, Finland

²Oulu University Hospital, Oulu, Finland

³Division of Operative Care, Oulu University Hospital, Oulu, Finland

ABSTRACT.

Purpose: To compare the performance and image quality of the handheld fundus camera to standard table-top fundus cameras in diabetic retinopathy (DR) screening. The reliability and diagnostic accuracy of DR grading performed by an ophthalmologist and a photographer reader were evaluated.

Materials and methods: 157 patients with diabetes, attending screening or follow-up of DR, were evaluated by fundus photographs taken in mydriasis by Optomed Aurora and Canon or Zeiss Visucam fundus cameras. The image quality and the severity of DR were evaluated independently by an ophthalmologist and experienced photographer. The sensitivity, specificity and reliability of the assessments were determined.

Results: 1884 fundus images from 314 eyes were analysed. In 53% of all eyes, DR was not present. 10% had mild non-proliferative diabetic retinopathy (NPDR), 16% moderate NPDR, 6% severe NPDR and 16% proliferative diabetic retinopathy (PDR). The DR grading outcomes by Aurora highly equalled to those of Canon or Zeiss ($\kappa = 0.93$, 95% CI 0.91 to 0.94), and there was almost perfect agreement in grading between the ophthalmologist and photographer ($\kappa = 0.96$, 95% CI 0.95 to 0.97). The image quality of Aurora was sufficient for reliable assessment according to both graders in 84–88% of the cases.

Conclusion: The Optomed Aurora fundus camera seems appropriate for DR screening. The sufficient image quality and high diagnostic accuracy for DR grading are supportive for a less expensive and easily transportable screening system for DR. Immediate image grading carried out by a photographer would further improve and speed up the screening process in all settings.

Key words: diabetes – diabetic retinopathy – fundus images – handheld camera – image quality – screening

Acta Ophthalmol. 2021; 99: e1415–e1420

© 2021 The Authors. Acta Ophthalmologica published by John Wiley & Sons Ltd on behalf of Acta Ophthalmologica Scandinavica Foundation.

This is an open access article under the terms of the Creative Commons Attribution License, which permits use, distribution and reproduction in any medium, provided the original work is properly cited.

doi: 10.1111/aos.14850

Introduction

Diabetic retinopathy (DR) is still one of the primary causes of vision loss worldwide (Leasher et al. 2016). Almost half a billion people are diagnosed with diabetes globally, and the number is expected to increase to 700 million people by the year 2045. Moreover, half of the people living with diabetes lack diagnosis (Saeedi et al. 2019). At least, some form of DR is estimated in 35% of the patients with diabetes and 10% of them have vision-threatening DR (Yau et al. 2012). DR is, however, often symptomless even in severe stages when treatment would be necessary in order to avoid further development of sight-threatening complications. Fortunately, even early changes of DR can be detected by fundus examination, and timely intervention may prevent or reduce vision loss. It is, thus, important that patients with diabetes are screened regularly in case of DR by ophthalmic examination or, more frequently, by fundus photography.

In Finland, each patient with either type 1 or type 2 diabetes is entitled to regular screening by fundus photography according to the Current Care Guideline for DR (Summanen et al. 2015). The screening system in Northern Finland has been further developed by organizing a mobile eye examination unit named EyeMo notably for the rural areas in order to provide equal access to screening for all patients

(Hautala et al. 2009). The earlier detection of DR by more effective screening and early treatment has led to the substantial, almost 90%, reduction of visual impairment in patients with diabetes in Northern Finland (Hautala et al. 2014). Thus, DR screening is not only cost-effective, but it may even save costs due to significant expenses caused by visual loss.

Retinal photography by standard table-top fundus cameras and manual reading of images by an ophthalmologist or a trained health-care professional are common approaches in screening of DR (Lanzetta et al. 2020). A handheld and easily movable fundus camera might serve as an alternative tool for organizing screening of DR in a cost-effective manner (Davila et al. 2017). It is possible to speed up the screening process by grading the stage of DR by a photographer immediately after shooting the images. Thus, we compared the performance of the portable Optomed Aurora fundus camera to that of traditional table-top fundus cameras for image quality and DR detection in a pilot study. The sensitivity, specificity and reliability of DR grading by an ophthalmologist and an experienced photographer were also evaluated.

Materials and Methods

This study was carried out at Oulu University Hospital and its mobile eye research unit EyeMo. The study followed the tenets of the Declaration of Helsinki, and it was conducted with the approval of the Oulu University Hospital Research Committee.

A total of 157 patients were included in the pilot study. In the first phase, 107 consecutive patients with either type 1 or type 2 diabetes attending screening of DR in EyeMo were evaluated. The black-and-white 45° fundus photographs were taken by an ophthalmic photographer first with the traditional table-top fundus camera (Canon CF-1) after pupil dilation with 1% tropicamide. Mydriatic was used to improve the image quality. Consecutively, another set of colour and black-and-white fundus images were taken with the handheld Optomed Aurora fundus camera in mydriasis (Optomed Aurora, Optomed, Finland). The impact of patient collaboration during the photography was considered equal, since fundus images by separate cameras were taken one after another in identical conditions. This portable camera has a 50° field of view, non-mydriatic operation, nine internal fixation targets and Wifi for transmitting images to the PC. Secondly, another 50 patients with more severe cases of DR and other retinal changes (age-related macular degeneration, retinal vein occlusion, etc.) attending follow-up visits in the hospital's outpatient eye clinic were examined. 45° fundus photography was performed after mydriasis with a table-top fundus camera (Zeiss Visucam 524), and 50° photography was performed with Optomed Aurora by the same photographer. From each patient, a total of twelve fundus images taken by separate cameras were included in the study (black-and-white papilla- and macula-centred images by the table-top and handheld cameras

and additional colour papilla- and macula-centred images by the handheld camera from both eyes of each patient). Each set of two-field images were analysed by using the high-quality 27" screens. Demographics were not collected (Fig. 1).

The quality of the black-and-white images taken by handheld or table-top cameras was graded according to the criteria described earlier by Boucher et al. (Boucher et al. 2005). Quality grades 1, 2, and 3 were considered as sufficient for interpretation (Table 1). Classification of the severity stage of DR was performed using the five-scale grading system developed by the Finnish Current Care Guidelines as shown in Table 2 (Summanen et al. 2015). The stages 2 (moderate background retinopathy), 3 (severe background retinopathy) and 4 (proliferative diabetic retinopathy) were considered as referable in the DR screening programme. The overall level of DR of each patient and the need for a referral to ophthalmologist were determined from the stage of DR in an eye with more severe changes. The ophthalmologist's grading of DR in black-and-white images taken with the traditional table-top fundus camera was used as a gold standard when calculating the sensitivity, specificity and reliability of the reading outcomes. The severity of DR and the image quality were analysed independently by the ophthalmologist reader and the photographer. In addition, any other retinal abnormalities were also documented for attention. The images from each camera were graded independently at different

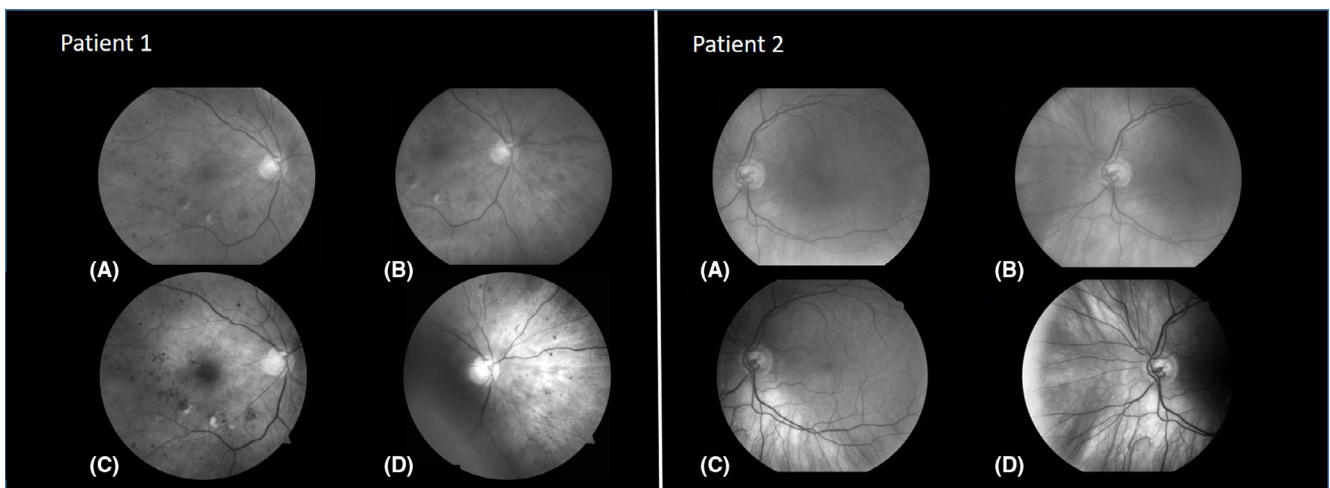


Fig. 1. The figure shows the examples of the macula- and papilla-centred fundus images taken by the handheld fundus camera (A and B) and the table-top fundus camera (C and D) from two individual patients with diabetes.

Table 1. The fundus image quality analysis was performed using a 5-grade classification, and the grades 1, 2, and 3 were considered to be of sufficient quality for interpretation for diabetic retinopathy. The criteria for each quality level have been described earlier (Boucher et al. 2005).

Grade	The criteria for the classification of the image quality	Quality for interpretation
1	Excellent definition	Sufficient for interpretation (grades 1-3)
2	Good definition of most details	
3	Definition limited but permitting confident assessment	
4	Insufficient definition for confident assessment	Not sufficient for interpretation (grades 4-5)
5	Only gross or no details visible	

Table 2. The classification of diabetic retinopathy used in the present study according to the Finnish Current Care Guideline. Severity grades 0 (no retinopathy) and 1 (mild background retinopathy) were considered as non-referable in the diabetic retinopathy screening setting.

Grade	Classification	Definition	Need for referral
0	No retinopathy	Normal fundus	Non-referable (grades 0-1)
1	Mild background retinopathy	Microaneurysms only	
2	Moderate background retinopathy	More than just microaneurysms but less than severe non-proliferative diabetic retinopathy	Referable (grades 2-4)
3	Severe background retinopathy (pre-proliferative retinopathy)	Any of the following: more than 20 intraretinal haemorrhages in each of 4 quadrants; definite venous beading in 2+ quadrants; Prominent intraretinal microvascular abnormalities in 1+ quadrant and no signs of proliferative retinopathy	
4	Proliferative retinopathy	One or more of the following: neovascularization, vitreous/pre-retinal haemorrhage	

time points, and all patient information was anonymous for the grader.

Statistical analyses

A paired-samples *t*-test was used to calculate the mean difference in quality assessment from the same image between the photographer and the ophthalmologist. Sensitivity and specificity were calculated to evaluate diagnostic accuracy. Furthermore, we calculated the weighted kappa (κ) to evaluate the agreement of the degree of DR. The kappa coefficient was calculated according to Yang & Zhou (2015), where the clustering of the data

(within-patient-eyes are more related than between-patient-eyes) was taken into consideration. The interpretation in regard to the kappa coefficient is as follows: $\kappa < 0$ as poor, 0.00–0.20 as slight, 0.21–0.40 as fair, 0.41–0.60 as moderate, 0.61–0.80 as substantial and 0.81–1.00 as almost perfect. A ninety-five % confidence interval (95% CI) is presented for mean difference, κ , sensitivity and specificity. Weighted κ was calculated by means of SAS macro provided by Yang and Zhou; all other analyses were calculated by SPSS for windows (IBM Corp. Released 2017. IBM spss Statistics for Windows, Version 25.0. Armonk, NY: IBM Corp.).

Results

A total of 1884 fundus images taken with the commonly used table-top fundus cameras (Canon CF-1 or Zeiss Visucam 524) and Optomed Aurora were analysed. 107 out of the 157 patients included in the study were attending DR screening, and the remaining 50 patients were attending follow-up visits at the hospital’s outpatient clinic as a result of more advanced DR. 68% of the eyes of the patients attending regular DR screening had no DR, 13% had mild non-proliferative diabetic retinopathy (NPDR), 13% moderate NPDR and 1% severe NPDR. Only, 4% of the eyes of the screening patients had proliferative diabetic retinopathy (PDR). Out of all the eyes in the study, more than a half (53%) had no signs of DR. Mild NPDR was detected in 10%, moderate NPDR in 16%, severe NPDR in 6% and PDR in 16% (Table 3). Detected retinal abnormalities other than DR were choroidal nevus (17 patients), age-related macular degeneration (10 patients), central retinal vein occlusion (4 patients), branch retinal vein occlusion (2 patients) and macular pucker (2 patients).

The DR grading outcomes of the images taken by Optomed Aurora equalled highly to those of Canon or Zeiss (Table 4). There is almost perfect agreement in identifying DR from Aurora fundus images by the ophthalmologist ($\kappa = 0.93$, 95% CI 0.91 to 0.96) and the photographer ($\kappa = 0.89$, 95% CI 0.85 to 0.93) within the reference standard. In addition, there was almost perfect agreement ($\kappa = 0.95$, 95% CI 0.93 to 0.98) with the ophthalmologist and the photographer in identifying DR from fundus images taken by the table-top camera.

The ophthalmologist and the photographer had sensitivities of 91.8% (95% CI 97.8 to 100) and 91.2% (95% CI 85.4 to 95.2) when detecting any level of DR from Optomed Aurora fundus images. Specificities were 100% (95% CI 97.8 to 100) and 100% (95%

Table 3. The grading results for the severity of diabetic retinopathy by ophthalmologist and photographer reader in fundus images taken by traditional table-top fundus cameras and Optomed Aurora.

	Table-top fundus camera BW, n (%)					Optomed Aurora BW, n (%)				
	No NPDR	Mild NPDR	Moderate NPDR	Severe NPDR	PDR	No NPDR	Mild NPDR	Moderate NPDR	Severe NPDR	PDR
Ophthalmologist	165 (53)	30 (10)	50 (16)	18 (6)	49 (16)	177 (57)	25 (8)	68 (22)	1 (0)	41 (13)
Photographer	166 (54)	26 (8)	55 (18)	14 (5)	51 (16)	177 (57)	26 (8)	68 (22)	4 (1)	36 (12)

Table 4. The reliability of the grading of diabetic retinopathy by photographer reader compared to that of an ophthalmologist in fundus images taken by table-top cameras or Optomed Aurora.

	Ophthalmologist table-top camera (gold standard) clinical diagnosis, n (%)					Weighted Kappa (95% CI)
	No NPDR	Mild NPDR	Moderate NPDR	Severe NPDR	PDR	
Ophthalmologist Aurora BW						
No NPDR	162 (52)	12 (4)	3 (1)	0	0	0.93 (0.91-0.96)
Mild NPDR	1 (0)	18 (6)	6 (2)	0	0	
Moderate NPDR	2 (1)	0	41 (13)	17 (5)	8 (3)	
Severe NPDR	0	0	0	1 (0)	0	
PDR	0	0	0	0	41 (13)	
Ophthalmologist Aurora colour						
No NPDR	165 (53)	14 (5)	5 (2)	0	0	0.93 (0.91-0.96)
Mild NPDR	0	16 (5)	5 (2)	0	0	
Moderate NPDR	0	0	40 (13)	18 (6)	8 (3)	
Severe NPDR	0	0	0	0	0	
PDR	0	0	0	0	41 (13)	
Photographer Aurora BW						
No NPDR	156 (50)	15 (5)	6 (2)	0	0	0.89 (0.85-0.93)
Mild NPDR	2 (1)	14 (5)	10 (3)	0	0	
Moderate NPDR	5 (2)	1 (0)	34 (11)	17 (6)	11 (4)	
Severe NPDR	1 (0)	0	0	1 (0)	2 (1)	
PDR	0	0	0	0	36 (12)	
Photographer Aurora colour						
No NPDR	163 (52)	17 (6)	7 (2)	0	0	0.91 (0.87-0.94)
Mild NPDR	0	13 (4)	14 (5)	0	0	
Moderate NPDR	0	0	29 (9)	17 (6)	9 (3)	
Severe NPDR	1 (0)	0	0	1 (0)	2 (1)	
PDR	0	0	0	0	38 (12)	
Photographer table top BW						
No NPDR	162 (52)	4 (1)	0	0	0	0.96 (0.93-0.98)
Mild NPDR	1 (0)	23 (7)	2 (1)	0	0	
Moderate NPDR	0	2 (1)	45 (14)	6 (2)	2 (1)	
Severe NPDR	2 (1)	0	2 (1)	9 (3)	1 (0)	
PDR	0	1 (0)	1 (0)	3 (1)	46 (15)	

CI 97.8 to 100), respectively (Table 5). Detection of referable DR (moderate NPDR and above) using the Aurora fundus images reached a sensitivity of 94.2% (95% CI 88.1 to 97.6) and a specificity of 100% (95% CI 98.1 to 100) in images graded by the ophthalmologist and a sensitivity of 92.3% (95% CI 86.9 to 96.4) and a specificity of 100% (95% CI 98.1 to 100) in images graded by the photographer. Furthermore, in detecting any DR or referable DR from images taken by the table-top cameras, the photographer obtained screening sensitivities of 99.3% (95% CI 96.3 to 100) and 100% (95% CI 96.9 to 100) and specificities of 100% (95% CI 97.8 to 100) and 98.5% (95% CI 95.6 to 99.7), respectively (Table 5).

The quality of the black-and-white fundus images taken by the table-top fundus cameras and Optomed Aurora was 1.4 and 2.5 when graded by the ophthalmologist, respectively. The photographer judged the quality of images taken with the Optomed Aurora fundus camera to grade 2.3. A

Table 5. The diagnostic accuracy of diabetic retinopathy grading by ophthalmologist and photographer in the black-and-white fundus images taken by table-top fundus cameras and Optomed Aurora.

	Cut-off	Diagnostic accuracy	
		Sensitivity (95% CI)	Specificity (95% CI)
Ophthalmologist (Aurora BW)	Any DR	91.8 (86.2-95.7)	100 (97.8-100)
	Referable DR (3, 4, 5)	94.2 (88.1-97.6)	100 (98.1-100)
	Severe NPDR, PDR	62.7 (50.0-74.2)	100 (98.5-100)
	PDR	83.7 (70.3-92.7)	100 (98.6-100)
Photographer (Aurora BW)	Any DR	91.2 (85.4-95.2)	100 (97.8-100)
	Referable DR (3, 4, 5)	92.3 (86.9-96.4)	100 (98.1-100)
	Severe NPDR, PDR	59.7 (47.0-71.5)	100 (98.5-100)
	PDR	73.5 (58.9-85.1)	100 (98.6-100)
Photographer (table top fundus camera)	Any DR	99.3 (96.3-100)	100 (97.8-100)
	Referable DR (3, 4, 5)	100 (96.9-100)	98.5 (95.6-99.7)
	Severe NPDR, PDR	97.0 (89.6-99.6)	100 (17.1-26.5)
	PDR	100 (92.8-100)	99.2 (97.3-99.9)

majority, 84% and 88%, of the images taken by Optomed Aurora fulfilled the criteria of sufficient quality for interpretation analysed by the ophthalmologist and the photographer, respectively. The quality of both macula- and papilla-centred fundus images was similar. Three per cent of these patients could not be reliably

photographed by either commonly used table-top fundus cameras due to insufficient fundus visibility (cataract, corneal or vitreous haze etc.).

Discussion

The results of the current pilot study show that the diagnostic performance

of a handheld Optomed Aurora fundus camera might be appropriate for the screening of DR. Moreover, the reliability of DR grading performed by the photographer was excellent, suggesting an opportunity to improve the DR screening process with immediate reading of DR after shooting the images. Screening for DR is an important but a substantial cost-effective aspect of diabetes management (Rohan et al. 1989; Javitt & Aiello 1996). Previous clinical trials have shown that up to 98% of visual loss due to DR could be prevented by timely treatment (Cheung et al. 2010; Tan et al. 2017). Improvements of screening programmes for early detection and intervention for DR are particularly important during the present era due to the enormous increase in the prevalence of diabetes as well as DR worldwide (Yau et al. 2012; Saeedi et al. 2019).

Retinal photography by standard table-top fundus cameras and manual reading of images by an ophthalmologist or a trained nurse are common approaches in screening of DR (Hautala et al. 2009, Lanzetta et al. 2020). Novel imaging technologies, such as wide- and ultrawide-field fundus cameras, would broaden the possibilities of fundus image screening. However, the size, weight and the cost of the traditional or novel table-top cameras set some limitations to their large-scale use, especially in areas lacking a sufficient operative screening process. A handheld and easily movable fundus camera might serve as an alternative and cost-effective tool for organizing screening of DR especially in countries with low health care and resource levels (Abegunde et al. 2007; Panwar et al. 2016; International Diabetes Foundation 2017). The Optomed Aurora fundus camera seems to perform appropriately in screening of DR with a sensitivity of 91.8% (95% CI 86.2% to 95.7%) and a specificity of 100% (95% CI 97.8 to 100%) in the current study reaching the targets of 80% in sensitivity and 90% to 95% in specificity for DR assessment which has been widely recommended by international retina experts (British Diabetic Association 1997; Canadian Ophthalmological Society Diabetic Retinopathy Clinical Practice Guideline Expert Committee et al. 2012).

The quality of Optomed Aurora black-and-white images fulfilled the criteria of sufficient quality for

interpretation in a majority, 84-88%, of the cases in the present study. This is in line with the previous study, where 12% of the fundus images taken by a non-mydratic camera (iCam-Optovue) after pupil dilation showed insufficient image quality to allow reading (Boucher et al. 2020). It is notable, though, that 97% of the black-and-white images taken with the traditional table-top fundus cameras in the present study reached the level of the sufficient quality for reliable grading of DR. The quality of the images was reduced in 3% of the patients with cataract and corneal or vitreous haze despite the type of the fundus camera used. A previous study suggested that the level of training of the fundus photographers might not affect the quality of images (Maberley et al. 2004). In our study, a notable amount (97%) of images taken by an expert photographer were of good quality, suggesting that the experience of the photographer might be crucial for the high frequency of the availability of qualified fundus photographs. The expertise of a photograph reader is also emphasized in the screening process according to the reliable detection of retinal findings other than DR. In our study, no cases of misreading by the photographer occurred in patients requiring referral to an ophthalmologist due to retinal occlusions or wet age-related macular degeneration.

Despite numerous recommendations and broad consensus of the importance of DR screening, adherence to regular screening is inadequate in many communities, possibly due to lack of resources, an effective screening programme or trained health-care professionals. Manual screening using fundus photographs involves considerable costs for both the patients and the entire health-care system, which may have limited its application at least in low-income settings. Telemedicine-based screening programmes with digital fundus photography have managed to increase the demand for DR screening, in addition to telemedicine technology having the potential to be cost-effective (Hautala et al. 2014; Kalogeropoulos et al. 2020; Avidor et al. 2020). However, artificial intelligence (AI) and several deep learning technologies have recently raised the possibility of a widespread automated screening system in the future (Lim et al. 2020; Vujosevic et al. 2020; Chaudhary 2020; Shah et al. 2020). Still,

more research is needed to address the potential clinical deployment and cost-effectiveness of such solutions before being widely accepted in the everyday clinical practice.

Meanwhile, any tools which improve DR screening and management will help in decreasing the burden of tackling this potential cause of blindness. In this study, we evaluated whether an ophthalmic photographer could read fundus images and assess DR grading immediately after shooting the photographs. An almost perfect agreement ($\kappa = 0.96$ (95% CI 0.95 to 0.97)) was noted in identifying the presence and severity of DR by the ophthalmologist and the photographer. Screening sensitivities of 100% and 100%, and specificities of 98.7% and 98.5% were obtained by the photographer in detecting any DR or identification of referable DR, respectively. Boucher et al. have revealed comparable 91% and 97% sensitivities, and 95% and 85% specificities in detecting any DR, and 86.8% and 91.2% sensitivities, and 91.7% and 97.0% specificities in detecting sight-threatening diseases by two nurse DR readers (Boucher et al. 2020). A similar DR grader sensitivity of 92.5% and specificity of 88% was reported by Goatman et al. (2012). Interestingly, recent studies by Bhargava et al. and McKenna et al. showed better diagnostic accuracy in DR grading among non-medical graders compared to that of family physicians or rural doctors (Bhargava et al. 2012; McKenna et al. 2018). These results are in line with our suggestion to improve DR screening by involving a non-medical photographer reader in the process as the first-line grader. The resources for screening would thus be used efficiently, and the screening process would speed up if the stage of DR would be graded immediately after shooting the images.

The limitations of this pilot screening study include the small number of graders, which only validates the individual performance of these readers, and the results may not apply to other readers due to the possible variations in performance and experience. However, several countries have clear recommendations for classification of DR and guidelines for referral to ophthalmologist that helps to standardize the interpretation in DR screening (Summanen et al. 2015; Wong et al. 2018). To further validate the use of the handheld camera in regular DR screening, several

screening centres and graders should be involved. The strength of the study is a relatively high amount of fundus images included in the comparative evaluation of the two imaging methods. Study patients include those attending regular screening for DR, but also those with more severe DR and other retinal abnormalities followed-up in hospital. The performance of Optomed Aurora would thus have been even better for just sorting out healthy eyes from those with any DR in the pure screening setting.

In conclusion, our results show that the handheld Optomed Aurora fundus camera performs well in DR screening according to the high sensitivity and specificity of DR detection as well as the image quality. We suggest that photographers could be more involved in DR grading leading to fewer delays in the screening process. This would not only improve the screening process, but also save time and reduce the need for resources, in addition to lowering expenses of DR screening with no compromises in the reliability of the outcomes.

References

- Abegunde DO, Mathers CD, Adam T, Ortegón M & Strong K (2007): The burden and costs of chronic diseases in low-income and middle-income countries. *Lancet* **370**: 1929–1938.
- Avidor D, Loewenstein A, Waisbourd M & Nutman A (2020): Cost-effectiveness of diabetic retinopathy screening programs using telemedicine: a systematic review. *Cost Eff Resour Alloc* **18**: 16.
- Bhargava M, Cheung CY, Sabanayagam C et al. (2012): Accuracy of diabetic retinopathy screening by trained non-physician graders using non-mydiatic fundus camera. *Singapore Med J* **53**: 715–719.
- Boucher MC, Nguyen QT & Angioi K (2005): Mass community screening for diabetic retinopathy using a nonmydiatic camera with telemedicine. *Can J Ophthalmol* **40**: 734–742.
- Boucher MC, Qian J, Brent MH et al. (2020): Evidence-based Canadian guidelines for tele-retina screening for diabetic retinopathy: recommendations from the Canadian Retina Research Network (CR2N) Tele-Retina Steering Committee. *Can J Ophthalmol* **55**: 14–24.
- British Diabetic Association (1997): Retinal photography screening for diabetic eye disease: A British diabetic association report. London: British Diabetic Association.
- Canadian Ophthalmological Society Diabetic Retinopathy Clinical Practice Guideline Expert Committee, Hooper P, Boucher MC et al. (2012): Canadian ophthalmological society evidence-based clinical practice guidelines for the management of diabetic retinopathy – executive summary. *Can J Ophthalmol* **47**: 91–96.
- Chaudhary V (2020): Tele-retina screening for diabetic retinopathy. *Can J Ophthalmol* **55**: 1.
- Cheung N, Mitchell P & Wong TY (2010): Diabetic retinopathy. *Lancet* **376**: 124–136.
- Davila JR, Sengupta SS, Niziol LM et al. (2017): Predictors of photographic quality with a handheld nonmydiatic fundus camera used for screening of vision-threatening diabetic retinopathy. *Ophthalmologica* **238**: 89–99.
- Goatman KA, Philip S, Fleming AD et al. (2012): External quality assurance for image grading in the Scottish Diabetic Retinopathy Screening Programme. *Diabet Med* **29**: 776–783.
- Hautala N, Aikkila R, Korpelainen J, Kesitalo A, Kurikka A, Falck A, Bloigu R & Alanko H (2014): Marked reductions in visual impairment due to diabetic retinopathy achieved by efficient screening and timely treatment. *Acta Ophthalmol* **92**: 582–587.
- Hautala N, Hyytinen P, Saarela V, Hägg P, Kurikka A, Runtti M & Tuulonen A (2009): A mobile eye unit for screening of diabetic retinopathy and follow-up of glaucoma in remote locations in northern Finland. *Acta Ophthalmol* **87**: 912–913.
- International Diabetes Foundation (2017): Diabetes: facts and figures. Available at: <http://www.idf.org/about-diabetes/facts-figures>. (Accessed on 1 Dec 2017).
- Javitt JC & Aiello LP (1996): Cost-effectiveness of detecting and treating diabetic retinopathy. *Ann Intern Med* **124**: 164–169.
- Kalogeropoulos D, Kalogeropoulos C, Stefanidou M & Neofytou M (2020): The role of tele-ophthalmology in diabetic retinopathy screening. *J Optom* **13**: 262–268.
- Lanzetta P, Sarao V, Scanlon PH et al. (2020): Fundamental principles of an effective diabetic retinopathy screening program. *Acta Diabetol* **57**: 785–798.
- Leasher JL, Bourne RR, Flaxman SR et al. (2016): Global estimates on the number of people blind or visually impaired by diabetic retinopathy: a meta-analysis from 1990 to 2010. *Diabetes Care* **39**: 1643–1649.
- Lim G, Bellemo V, Xie Y, Lee XQ, Yip MYT & Ting DSW (2020): Different fundus imaging modalities and technical factors in AI screening for diabetic retinopathy: a review. *Eye Vis (Lond)* **7**: 21.
- Maberley D, Morris A, Hay D, Chang A, Hall L & Mandava N (2004): A comparison of digital retinal image quality among photographers with different levels of training using a non-mydiatic fundus camera. *Ophthalmic Epidemiol* **11**: 191–197.
- McKenna M, Chen T, McAnaney H et al. (2018): Accuracy of trained rural ophthalmologists versus non-medical image graders in the diagnosis of diabetic retinopathy in rural China. *Br J Ophthalmol* **102**: 1471–1476.
- Panwar N, Huang P, Lee J et al. (2016): Fundus photography in the 21st century—a review of recent technological advances and their implications for worldwide healthcare. *Telemed J E Health* **22**: 198–208.
- Rohan TE, Frost CD & Wald NJ (1989): Prevention of blindness by screening for diabetic retinopathy: a quantitative assessment. *BMJ* **299**: 1198–1201.
- Saeedi P, Petersohn I, Salpea P et al. (2019): Global and regional diabetes prevalence estimates for 2019 and projections for 2030 and 2045: results from the International Diabetes Federation Diabetes Atlas, 9th edition. *Diabetes Res Clin Pract* **157**: 107843.
- Shah P, Mishra DK, Shanmugam MP, Doshi B, Jayaraj H & Ramanjulu R (2020): Validation of Deep Convolutional Neural Network-based algorithm for detection of diabetic retinopathy - Artificial intelligence versus clinician for screening. *Indian J Ophthalmol* **68**: 398–405.
- Summanen P, Kallioniemi V, Komulainen J, Eriksson L, Forsvik H, Hietala K, Tulokas S & Von Wendt G (2015): Current care guideline: diabetic retinopathy. *Duodecim* **131**: 893–894.
- Tan GS, Cheung N, Simó R, Cheung GC & Wong TY (2017): Diabetic macular oedema. *Lancet Diabetes Endocrinol* **5**: 143–155.
- Vujosevic S, Aldington SJ, Silva P, Hernández C, Scanlon P, Peto T & Simó R (2020): Screening for diabetic retinopathy: new perspectives and challenges. *Lancet Diabetes Endocrinol* **8**: 337–347.
- Wong TY, Sun J, Kawasaki R et al. (2018): Guidelines on diabetic eye care: the International Council of Ophthalmology recommendations for screening, follow-up, referral, and treatment based on resource settings. *Ophthalmology* **125**: 1608–1622.
- Yang Z & Zhou M (2015): Weighted kappa statistic for clustered matched-pair ordinal data. *Comput Stat Data Anal* **82**: 1–18.
- Yau JW, Rogers SL, Kawasaki R et al. (2012): Global prevalence and major risk factors of diabetic retinopathy. *Diabetes Care* **35**: 556–564.

Received on July 8th, 2020.

Accepted on February 23rd, 2021.

Correspondence:

Nina Hautala
 Department of Ophthalmology
 University of Oulu
 Oulu University Hospital and MRC Oulu
 P.O. Box 21, 90029 OYS
 Finland
 Tel: +358-8-315 3726
 Emails: nina.hautala@oulu.fi;
 nina.hautala@ppshp.fi