

# Double vs single primary tooth extraction in interceptive treatment of palatally displaced canines: *A randomized controlled trial*

Sigurd Hadler-Olsen<sup>a</sup>; Anders Sjögren<sup>b</sup>; Jeanett Steinnes<sup>c</sup>; Mari Dubland<sup>d</sup>;  
Napat Limchaichana Bolstad<sup>e</sup>; Pertti Pirttiniemi<sup>f</sup>; Heidi Kerosuo<sup>g</sup>; Raija Lähdesmäki<sup>h</sup>

## ABSTRACT

**Objectives:** To compare the impact of primary canine and primary first molar extractions with extractions of only the primary canine regarding correction of palatally displaced canines (PDCs).

**Materials and Methods:** Thirty-two children aged 9.5–13.5 years with 48 PDCs were randomly allocated to either the double-extraction group (DEG) or single-extraction group (SEG). Clinical and radiographic examinations were performed at baseline and at 6-month intervals until the canine emerged or orthodontic treatment was started. Outcome measures were: emergence of maxillary canine (yes/no), emergence of maxillary canine into a favorable position (yes/no), and maxillary canine positional change (angulation and sector). Factors influencing PDC emergence were analyzed using logistic regression.

**Results:** In the DEG, 64% (16/25) of canines emerged into the oral cavity vs 78% (18/23) in the SEG ( $P = .283$ ). Favorable PDC position at trial end was seen in 64% (16/25) of the DEG vs 57% (13/23) of the SEG ( $P = .600$ ). Significant distal movement of PDCs was recorded in the DEG and SEG, though no significant difference was observed between groups. Significant predictors of canine emergence were initial canine angulation (Angle A) ( $P = .008$ ) and space conditions at  $T_0$  ( $P = .030$ ).

**Conclusions:** Double or single primary tooth extraction procedures are equivalent in supporting PDC eruption into the oral cavity and into a favorable position in the dental arch. Initial canine angulation and space assessments may be used as predictors of successful PDC eruption. (*Angle Orthod.* 2020;90:751–757.)

**KEY WORDS:** Ectopic canine; Interceptive treatment; Primary tooth extraction

## INTRODUCTION

The maxillary canine is an important tooth from both the esthetic and functional perspectives. Ectopic eruption and impaction are not very frequent (1%–3%

prevalence)<sup>1–3</sup> but can create problems if left untreated. Such problems may be mispositioning and retention of the ectopic tooth, external root resorption, migration of neighboring teeth, dentigerous cyst formation, referred pain, and other complications.<sup>4</sup> To avoid complications,

<sup>a</sup> Research Fellow, Public Dental Health Service Competence Centre of Northern Norway, Tromsø, Norway.

<sup>b</sup> Associate Professor, Institute of Clinical Dentistry, Faculty of Health Sciences, UiT The Arctic University of Norway, Tromsø, Norway.

<sup>c</sup> Orthodontist, Public Dental Health Service Competence Centre of Northern Norway, Tromsø, Norway.

<sup>d</sup> Orthodontist, Private Practice, Bryne, Norway.

<sup>e</sup> Associate Professor, Institute of Clinical Dentistry, Faculty of Health Sciences, UiT The Arctic University of Norway, Tromsø, Norway.

<sup>f</sup> Professor, Research Unit of Oral Health Sciences, Faculty of Medicine, University of Oulu, Oulu, Finland.

<sup>g</sup> Professor, Institute of Clinical Dentistry, Faculty of Health Sciences, UiT The Arctic University of Norway, Tromsø, Norway.

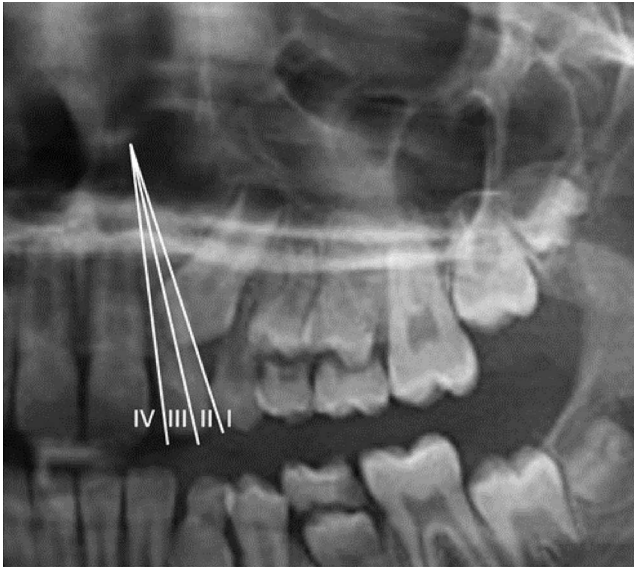
<sup>h</sup> Associate Professor, Research Unit of Oral Health Sciences, Faculty of Medicine, University of Oulu, Oulu, Finland.

Corresponding author: Sigurd Hadler-Olsen, Public Dental Health Service Competence Centre of Northern Norway, Postboks 2406, 9271 Tromsø, Norway  
(e-mail: sigurd.hadler-olsen@tffk.no)

Accepted: May 2020. Submitted: March 2020.

Published Online: July 21, 2020

© 2020 by The EH Angle Education and Research Foundation, Inc.



**Figure 1.** Sector location of the maxillary canine.

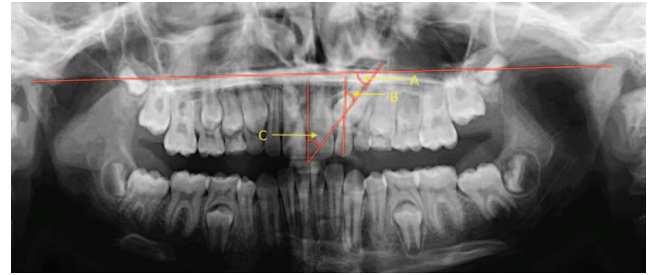
interceptive treatment has been suggested, and several studies have evaluated the effects of such treatment.<sup>5–12</sup> Considerable variation in study design, sample size, and research approach has produced conflicting results, making it difficult to evaluate the conclusions drawn.<sup>13</sup> The most widely suggested interceptive treatment approach in cases of palatally displaced maxillary canines is extraction of the deciduous maxillary canine.<sup>14</sup> This approach could increase the emergence rate of palatally displaced canines (PDCs) from 39% to 42% without extraction, to 67% to 69% with the primary canine extracted.<sup>10,11</sup> A recent study compared the effects of extracting both the primary canine and primary first molar with extracting the primary canine only. The researchers reported that the double-extraction procedure was significantly more beneficial than extracting the primary canine only.<sup>12</sup> However, few studies using this procedure exist, and the evidence of its benefits is limited.

The main objective of this study was to investigate whether extracting the primary canine and primary first molar was more beneficial than extracting only the primary canine in improving the emergence rate of PDCs. Furthermore, changes in PDC position were evaluated, and predictors of PDC emergence into the oral cavity were analyzed.

## MATERIALS AND METHODS

### Trial Design

This study was designed as a randomized controlled clinical trial with an allocation ratio of 1:1 to either



**Figure 2.** Angular measurements of maxillary canines. Angle A indicates canine to bicondylar line; Angle B, canine to lateral incisor; Angle C, canine to maxillary midline.

1. the double-extraction group (DEG): extraction of both the primary canine and the primary first molar; or
2. the single-extraction group (SEG): extraction of the primary canine only.

Due to strong recommendations to treat this patient group,<sup>13</sup> it was considered unethical to have an untreated control group.

### Ethics

The regional ethical committee of Northern Norway approved the study in June 2012 (2012/623/REK Nord). Informed consent was obtained from the child and parent or from an adult with parental responsibilities and rights. All procedures were conducted in accordance with the Declaration of Helsinki.<sup>15</sup>

### Subjects

All patients, 9.5–13.5 years old, examined at the Public Dental Health Competence Centre of Northern Norway and one private clinic in Bryne, Norway, diagnosed with unilateral or bilateral PDC between 2013 and 2018, were invited to participate in the study.

### Inclusion Criteria

The following inclusion criteria were used:

- Dental age of 9.5 and 10.5 years<sup>16</sup> and the presence of both primary maxillary canines and primary maxillary first molars.
- Palatal position of the canine verified by taking two periapical radiographs and by using the Same Lingual Opposite Buccal (SLOB) rule.<sup>17</sup>
- Eruption of the maxillary canine in sectors III and IV according to Lindauer et al.<sup>18</sup> (Figure 1) or of the maxillary canine in sector II with an angle between the long axis of the canine and the facial midline (Angle C) of at least 25° (Figure 2)<sup>19</sup> assessed on panoramic radiographs.

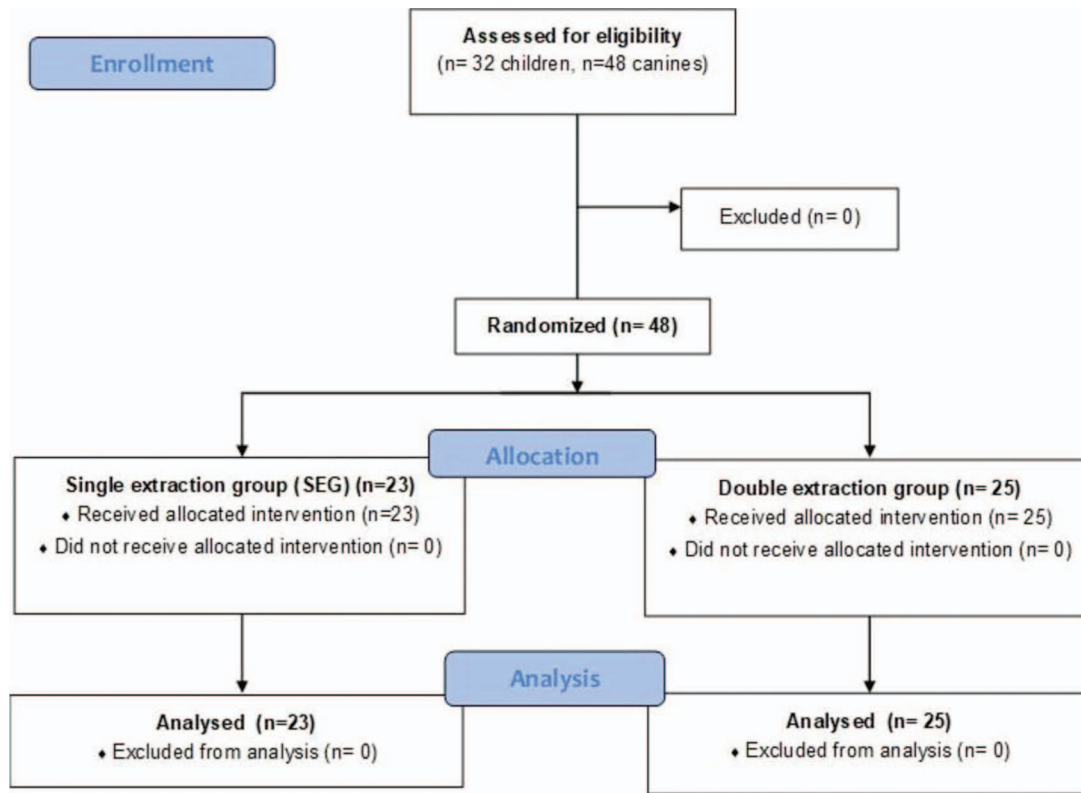


Figure 3. Consort flow diagram of participants in the study.

**Exclusion Criteria**

The following exclusion criteria were used:

- Agenesis of maxillary lateral incisor.
- Previous orthodontic treatment.
- Any disease preventing local anesthesia or extraction.
- Craniofacial syndromes, cleft lip/palate, odontomas, or cysts.

**Final Study Sample**

Thirty-two children, 18 girls and 14 boys, with a mean age ( $\pm$  standard deviation [SD]) of  $10.7 \pm 0.7$  and  $11.2 \pm 1.0$  years, respectively, were invited to participate in the study; all accepted. Sixteen children had bilateral PDCs, and each single canine served as a separate unit in the study. In total, 48 PDCs were included in the study (Figure 3).

The children were examined clinically, including taking a panoramic radiograph before the study ( $T_0$ ) and every 6 months until the canine erupted into the mouth ( $T_1$ – $T_x$ ). If the canine position worsened or improvement was undetectable after 12 months, alternative treatment was administered (ie, surgical exposure, fixed orthodontic appliances). Clinical photos were taken of each participant before and at the end of the study.

**Measurements**

Panoramic radiographs were taken using a Soredex Cranex D x-ray system (Soredex, Tuusula, Finland) according to the manufacturer’s settings. Angles A, B, and C<sup>20</sup> (Figure 2) and Sector<sup>18</sup> (Figure 1) were measured by a faculty member of the University of Tromsø, Norway using version 3.10 of the Facad tracing program (Ilaxis, Linköping, Sweden). Measurement reliability was reported in a previous study.<sup>20</sup>

**Space Conditions**

Clinical photos were examined by an experienced orthodontist, and the dentitions were categorized as crowded, aligned, or spaced according to space mesial to the first maxillary molar (Figure 4).

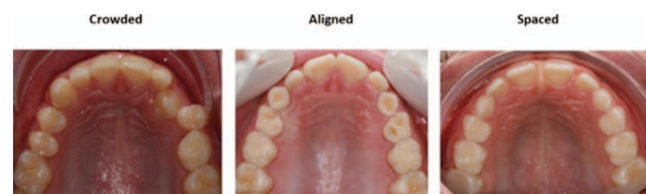

Figure 4. Space discrepancy assessment on clinical photographs. Crowded indicates one or more teeth are overlapping and displaced; aligned, all teeth are well aligned; spaced, open spaces between teeth.

## Primary Outcome

Following is the primary outcome:

- Emergence of the maxillary canine into the oral cavity (yes/no).
- Emergence of the maxillary canine into a favorable position.
  - o Maxillary canines erupted in sector I (Figure 1) in clinically normal buccopalatal relationship with occluding teeth in the mandible (yes/no).

## Secondary Outcome

Following is the secondary outcome:

- Maxillary canine positional changes.
  - o Angles A, B, and C (Figure 2).
  - o Sectors (Figure 1).

## Sample-Size Calculation

The sample size was based on mean changes ( $T_0$ – $T_1$ ) in Angle C ( $\alpha$ -angle) between the SEG and DEG in an earlier study.<sup>21</sup> Each of the two groups required 22 canines according to an estimation with  $\alpha = 0.05$ ,  $\beta = 0.2$ , and a power of 80%.

## Statistical Analysis

Descriptive statistics were used to report the data (mean, SD, minimum, maximum). The normality of the data was confirmed using the Kolmogorov–Smirnov and Shapiro–Wilk tests. An independent sample *t*-test was used to analyze baseline data as well as changes in continuous variables. The Mann–Whitney U test was used to evaluate the outcome of the variables emergence of the maxillary canine into the oral cavity and emergence of the maxillary canine into a favorable position. The Fisher exact test was used to test the association between space conditions in the maxillary arch at  $T_0$  and emergence of canines. The marginal homogeneity test was used to test within-group changes in ordinal data. To evaluate the association between various factors and emergence of the maxillary canine, a binary logistic regression was performed to calculate odds ratios and two-sided 95% confidence intervals. The level of significance was set at  $P < .05$ . Statistical analysis was performed using version 26.0 of the SPSS software package (SPSS Inc, Chicago, Ill).

## RESULTS

### Participant Flow

Canines were examined clinically and radiographically every 6 months until they emerged ( $n = 34$ ) or until

**Table 1.** Baseline Data ( $T_0$ ) for the Single-Extraction Group (SEG) and Double-Extraction Group (DEG)<sup>a</sup>

Variable	SEG (n = 23)	DEG (n = 25)	P Value*	
	Mean $\pm$ SD	Mean $\pm$ SD		
Age	11.0 $\pm$ 1.1	10.8 $\pm$ 0.7	.621	NS
Dental age	10.1 $\pm$ 0.5	9.8 $\pm$ 0.5	.067	NS
Angle A (°)	60.9 $\pm$ 7.8	62.1 $\pm$ 8.5	.626	NS
Angle B (°)	36.9 $\pm$ 9.5	35.1 $\pm$ 6.6	.485	NS
Angle C (°)	30.4 $\pm$ 9.1	27.1 $\pm$ 7.7	.183	NS
	n	n		
Crowding	1	2	A	NS
No crowding	5	5	A	NS
Spacing	17	18	A	NS
Sector 2	7	4	B	NS
Sector 3	12	18	B	NS
Sector 4	4	3	B	NS
Female	15	13	C	NS
Male	8	12	C	NS

<sup>a</sup> DEG indicates double-extraction group; NS, not significant; SD, standard deviation; SEG, single-extraction group.

\*  $P$  value  $< .05$  is considered statistically significant. <sup>A</sup> Mann–Whitney U test:  $P = .832$ . <sup>B</sup> Mann–Whitney U test:  $P = .586$ . <sup>C</sup> Mann–Whitney U test:  $P = .359$ .

orthodontic treatment was started due to worsened position (ie, increase in sector and/or Angle A) of the canine ( $n = 14$ ). Alternative orthodontic treatment was started at 6 months (2 children/3 canines), 12 months (6 children/7 canines), 18 months (1 child/1 canine), and 24 months (3 children/3 canines). The mean observation time for the studied sample was 14.8 months (range = 6–24 months). There were no dropouts in the study (Figure 3).

### Baseline Findings

There were no significant differences at baseline between the DEG and SEG (Table 1). Angular data were normally distributed in both groups.

### Primary Outcome

Emergence of the maxillary canine into the oral cavity:

- Sixteen of 25 canines in the DEG emerged vs 18 of 23 canines in the SEG (64% vs 78%;  $P = .283$ ).
- In the DEG, 40% of canines emerged within 12 months, 53% within 18 months, and 7% within 24 months vs 32%, 63%, and 5%, respectively, in the SEG ( $P = .732$ ).
- Unilateral and bilateral canines were equally distributed among the PDCs with unsuccessful eruption (7/14).

Emergence of the maxillary canine into a favorable position:

- In total, 64% of the canines emerged favorably in the DEG vs 57% in the SEG (16/25 vs. 13/23;  $P = .600$ ).



**Table 2.** Sector Change in PDCs From Start (T<sub>0</sub>) to End of Trial in the SEGs and DEGs

PDC T <sub>0</sub>	Worsened by One Sector		No Change		Improved by One Sector		Improved by Two Sectors		Improved by Three Sectors		Total
	SEG	DEG	SEG	DEG	SEG	DEG	SEG	DEG	SEG	DEG	
Sector 2	0	0	3	0	3	3	0	0	0	0	9
Sector 3	2	2	1	1	1	2	9	14	0	0	32
Sector 4	0	0	0	1	1	1	1	0	2	1	7
Total	2	2	4	2	5	6	10	14	2	1	48

<sup>a</sup> DEG indicates double-extraction group; improved sector, reduction in sector; PDC, palatally displaced canine; SEG, single-extraction group; worsened sector, increase in sector.

**Secondary Outcome**

Maxillary canine positional change:

- The angular and sector measurements indicated significant distal movement of the canines in both groups (*P* < .001), with wide individual variation (Table 2). However, no significant difference was found between the two groups for changes in canine angle or sector (Table 3).
- Of the 14 unerupted canines, improvement in the eruption path was seen in 56% in the DEG and 60% in the SEG. Six of all examined canines exhibited a worsened eruption path (ie, increase in sector and/or Angle A), four in the DEG and two in the SEG (*P* = .449).

Predictive factors for the emergence of the maxillary canine into the oral cavity:

- A significant relationship was observed between maxillary canine angulation at baseline (Angle A) and the emergence of PDCs (Odds ratio = 0.882, Confidence interval = 0.804–0.968; *P* = .008).
- Canines that emerged exhibited a significantly greater Angle A at T<sub>0</sub> than did non-emerged canines (mean = 63.7° ± 6.6° vs mean = 56.2° ± 9.1°; *P* = .003).
- A significant relationship was also seen between the emergence of PDCs and space discrepancy at T<sub>0</sub> (*P* = .030). More PDCs emerged the more space was available at T<sub>0</sub> (Figure 5).

**DISCUSSION**

The main objective of this study was to compare the emergence rate of PDCs when the primary canine and

the primary first molar were extracted compared with extraction of the primary canine only. The current study did not find a significant difference in emergence rate between these two procedures. In two previous studies, no difference in emergence rate between the groups was found in the first study,<sup>21</sup> but a significantly higher emergence rate in the DEG was observed in the second study.<sup>12</sup> One reason for the dissimilarity between these studies could be differences in dental developmental age in the participants. In the second study,<sup>12</sup> 43% of participants had a dental development age of 8.5 years<sup>16</sup> vs 100% in the 9.5- and 10.5-year-old stage in the present study. It was pointed out earlier that canines normally appear palatal in children younger than 10, which elevates the risk to include normal canines as PDCs in younger age samples.<sup>22</sup>

Differences in the initial canine position could also have influenced the emergence rate. In the present study, no canines were situated in sector I, 1/4 in sector II, 2/3 in sector III, and 7/48 in sector IV. In a study by Bonetti et al.,<sup>21</sup> 1/4 of canines were located in sector I and 2/3 in sector II. This indicated that the present study had more severe cases. The higher success rate for canine emergence in the Bonetti et al. study vs the present study could also have been related to a longer observation time in the previous studies (ie, 18 months vs 14.8 months).

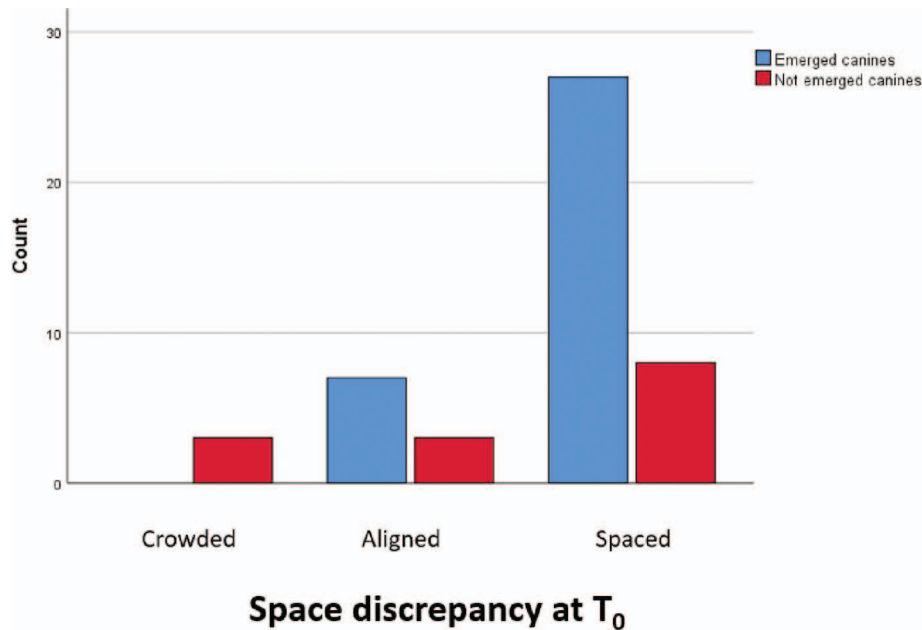
Bonetti et al.<sup>21</sup> emphasized that the ultimate criterion for successful outcome may not only be the rate of eruption/non-eruption of PDCs into the dental arch.<sup>21</sup> In agreement with this statement, it is also very important *where* in the mouth the canines emerge, as the distance from the emergence point and favorable position in the dental arch affects the orthodontic treatment length and cost.<sup>23</sup> In addition, the risk of root

**Table 3.** Comparison of Changes in Canine Angulation Between Initial and End Observations; Mean Observation Time = 14.8 Months

Variable	SEG			DEG			<i>P</i> Value*	
	Mean	Minimum	Maximum	Mean	Minimum	Maximum		
Angle A°	-15.3	-29.9	1.7	-14.7	-36.3	6.7	.846	NS
Angle B°	15.8	-2.5	38.6	14.9	-11.2	44.6	.818	NS
Angle C°	17.7	-2.7	43.9	13.3	-10.6	33.7	.203	NS

<sup>a</sup> DEG indicates double-extraction group; NS, not significant; SEG, single-extraction group.

\* *P* value < .05 is considered statistically significant, independent samples *t*-test.



**Figure 5.** Relationship between space discrepancy in maxillary arch at T<sub>0</sub> and emergence of PDCs. Crowded indicates one or more teeth are overlapping and displaced; aligned, all teeth are well aligned; spaced, spaces between maxillary teeth.

resorption is substantially reduced if the canine is localized in sector I.<sup>19</sup> Emergence of the maxillary canine into a favorable position was therefore added to the primary outcome. No significant difference was seen in this respect between the two extraction groups when all examined canines were analyzed. However, for canines that emerged into the oral cavity, significantly more canines emerged in a favorable position in the DEG than the SEG. The reason for this difference was unclear. Previous studies found that the angle between the first premolar and the facial midline increased more when double rather than single extractions were performed,<sup>21</sup> which may lead to a different eruption pattern for canines in the DEG than the SEG.

Canines in both the DEG and SEG changed to a significantly more vertical position from the initial to final observations ( $P < .001$ ), though no significant difference was found between the groups. This was in contrast to two previous studies finding that the DEGs experienced greater angular change than did the SEGs.<sup>12,21</sup> The amount of angular change in erupting canines may be related to space conditions and age and may, therefore, differ between individuals and study samples.<sup>20,24</sup> Therefore, the angular position of emerged canines may not be the best outcome variable, though it has been used in many PDC studies.<sup>5,6,11,12,21</sup> However, as a selection criterion for decisions regarding primary canine extraction and, as a predictive variable during the observation period, canine angulation may be important. In a recent study, Naoumova et al.<sup>25</sup> advocated guidelines for the

interceptive extraction of primary canines based on sector location and alpha angle. They suggested that interceptive extraction was beneficial when the canine was located in sector II or III with an alpha angle (Angle C) of 20°–30°. If the canine was located in sector IV, with an alpha angle >30°, immediate surgical exposure was recommended, and observation was recommended if the canine was located in sector II with an alpha angle ≤20°. If these guidelines had been applied to the present sample, they would have worked very well for the recommendations to extract the primary canine (23 of 26 canines emerged), but not as well for the recommendations to implement surgical exposure (three of four canines emerged without surgery).

Previous studies have shown that dental arch space was reduced after primary maxillary canine extraction.<sup>10</sup> In the present study, only photos and not dental models were made, which made accurate space measurements difficult. However, the photos could reveal that spaced maxillary arches at the start of the trial was significantly associated with emerged canines compared with aligned or crowded maxillary arches, but this result should be interpreted with some caution due to few cases in the crowded group. This was in line with earlier studies showing that increased maxillary dental arch space positively affected the PDC emergence rate.<sup>9,26,27</sup> It has also been reported that space conditions in the maxillary dental arch influenced the canine eruption path.<sup>20,24</sup>

The most important predictor of successful emergence into the oral cavity was the angle between the maxillary canine and the bicondylar line (Angle A) at T<sub>0</sub>.

Naoumova et al.<sup>25</sup> also found canine angulation, apart from primary canine extraction, to be the best predictor of PDC emergence, which was also confirmed by Power and Short.<sup>6</sup>

## CONCLUSIONS

- Double or single primary tooth extraction procedures are equivalent in supporting PDC eruption into the oral cavity and into a favorable position in the dental arch.
- Initial canine angulation and space assessments may be used as predictors of successful PDC eruption.

## ACKNOWLEDGMENTS

### Registration

The study was registered at ClinicalTrials.gov, number NCT02675036.

### Funding

No funding or other support was received to conduct this study.

### Conflict of Interest

None to declare.

## REFERENCES

1. Dachi SF, Howell FV. A survey of 3,874 routine full-month radiographs. II. A study of impacted teeth. *Oral Surg Oral Medicine Oral Pathol.* 1961;14:1165–1169.
2. Thilander B, Myrberg N. The prevalence of malocclusion in Swedish schoolchildren. *Scand J Dent Res.* 1973;81:12–21.
3. Ericson S, Kurol J. Radiographic assessment of maxillary canine eruption in children with clinical signs of eruption disturbance. *Eur J Orthod.* 1986;8:133–140.
4. Shafer WG HM, Levy BM. *A Textbook of Oral Pathology.* 4th ed. Philadelphia, PA: WB Saunders; 1983.
5. Ericson S, Kurol J. Early treatment of palatally erupting maxillary canines by extraction of the primary canines. *Eur J Orthod.* 1988;10:283–295.
6. Power SM, Short MB. An investigation into the response of palatally displaced canines to the removal of deciduous canines and an assessment of factors contributing to favourable eruption. *Br J Orthod.* 1993;20:215–223.
7. Bruks A, Lennartsson B. The palatally displaced maxillary canine. A retrospective comparison between an interceptive and a corrective treatment group. *Swed Dent J.* 1999;23:149–161.
8. Leonardi M, Armi P, Franchi L, Baccetti T. Two interceptive approaches to palatally displaced canines: a prospective longitudinal study. *Angle Orthod.* 2004;74:581–586.
9. Baccetti T, Leonardi M, Armi P. A randomized clinical study of two interceptive approaches to palatally displaced canines. *Eur J Orthod.* 2008;30:381–385.
10. Bazargani F, Magnuson A, Lennartsson B. Effect of interceptive extraction of deciduous canine on palatally displaced maxillary canine: a prospective randomized controlled study. *Angle Orthod.* 2014;84:3–10.
11. Naoumova J, Kurol J, Kjellberg H. Extraction of the deciduous canine as an interceptive treatment in children with palatal displaced canines—part I: shall we extract the deciduous canine or not? *Eur J Orthod.* 2015;37:209–218.
12. Alessandri Bonetti G, Zanarini M, Incerti Parenti S, Marini I, Gatto MR. Preventive treatment of ectopically erupting maxillary permanent canines by extraction of deciduous canines and first molars: a randomized clinical trial. *Am J Orthod Dentofacial Orthop.* 2011;139:316–323.
13. Naoumova J, Kurol J, Kjellberg H. A systematic review of the interceptive treatment of palatally displaced maxillary canines. *Eur J Orthod.* 2011;33:143–149.
14. Bishara SE. Impacted maxillary canines: a review. *Am J Orthod Dentofacial Orthop.* 1992;101:159–171.
15. World Medical Association Declaration of Helsinki: Ethical Principles for Medical Research Involving Human Subjects, JAMA 2013 Nov 27;310:2191–4.
16. AlQahtani SJ, Hector MP, Liversidge HM. Accuracy of dental age estimation charts: Schour and Massler, Ubelaker and the London Atlas. *Am J Phys Anthropol.* 2014;154:70–78.
17. Clark CA. Radiographs of the teeth and associated parts. *Proc R Soc Med.* 1909;2:39–46.
18. Lindauer SJ, Rubenstein LK, Hang WM, Andersen WC, Isaacson RJ. Canine impaction identified early with panoramic radiographs. *J Am Dent Assoc.* 1992;123:91–92, 95–97.
19. Hadler-Olsen S, Pirttiniemi P, Kerosuo H, et al. Root resorptions related to ectopic and normal eruption of maxillary canine teeth—a 3D study. *Acta Odontol Scand.* 2015;73:609–615.
20. Hadler-Olsen S, Pirttiniemi P, Kerosuo H, et al. Does headgear treatment in young children affect the maxillary canine eruption path? *Eur J Orthod.* 2018;40:583–591.
21. Bonetti GA, Parenti SI, Zanarini M, Marini I. Double vs single primary teeth extraction approach as prevention of permanent maxillary canines ectopic eruption. *Pediatr Dent.* 2010;32:407–412.
22. Peck S. Problematic sample in the study of interception of palatally displaced canines. *Am J Orthod Dentof Orthop.* 2011;140:2–3.
23. Bazargani F, Magnuson A, Dolati A, Lennartsson B. Palatally displaced maxillary canines: factors influencing duration and cost of treatment. *Eur J Orthod.* 2013;35:310–316.
24. Silvola AS, Arvonen P, Julku J, Lahdesmaki R, Kantomaa T, Pirttiniemi P. Early headgear effects on the eruption pattern of the maxillary canines. *Angle Orthod.* 2009;79:540–545.
25. Naoumova J, Kjellberg H. The use of panoramic radiographs to decide when interceptive extraction is beneficial in children with palatally displaced canines based on a randomized clinical trial. *Eur J Orthod.* 2018;40:565–574.
26. Sigler LM, Baccetti T, McNamara JA Jr. Effect of rapid maxillary expansion and transpalatal arch treatment associated with deciduous canine extraction on the eruption of palatally displaced canines: a 2-center prospective study. *Am J Orthod Dentof Orthop.* 2011;139:235–244.
27. Armi P, Cozza P, Baccetti T. Effect of RME and headgear treatment on the eruption of palatally displaced canines: a randomized clinical study. *Angle Orthod.* 2011;81:370–374.