




# Appendicolith appendicitis is clinically complicated acute appendicitis—is it histopathologically different from uncomplicated acute appendicitis

Jari Mällinen<sup>1,2</sup>  · Siina Vaarala<sup>3,4</sup> · Markus Mäkinen<sup>3,4</sup> · Elina Lietzén<sup>5,6</sup> · Juha Grönroos<sup>5,6</sup> · Pasi Ohtonen<sup>2</sup> · Tero Rautio<sup>1,2</sup> · Paulina Salminen<sup>5,6,7</sup>

Accepted: 10 June 2019 / Published online: 24 June 2019  
© The Author(s) 2019

## Abstract

**Purpose** Acute appendicitis may present as uncomplicated and complicated and these disease forms differ both epidemiologically and clinically. Complicated acute appendicitis has traditionally been defined as an appendicitis complicated by perforation or a periappendicular abscess, and an appendicolith represents a predisposing factor of complicated disease. There are histopathological differences between uncomplicated acute appendicitis and the previously established traditional forms of complicated acute appendicitis, but to our knowledge, the histopathological differences between uncomplicated acute appendicitis and complicated acute appendicitis presenting with an appendicolith have not yet been reported. The study purpose was to assess these differences with two prospective patient cohorts: (1) computed tomography (CT) confirmed uncomplicated acute appendicitis patients enrolled in the surgical treatment arm of the randomized APPAC trial comparing appendectomy with antibiotics for the treatment of uncomplicated acute appendicitis and (2) patients with CT-verified acute appendicitis presenting with an appendicolith excluded from the APPAC trial.

**Methods** The following histopathological parameters were assessed: appendiceal diameter, depth of inflammation, micro-abscesses, density of eosinophils, and neutrophils in appendiceal wall and surface epithelium degeneration.

**Results** Using multivariable logistic regression models adjusted for age, gender, and symptom duration, statistically significant differences were detected in the depth of inflammation  $\leq 2.8$  mm (adjusted OR 2.18 (95%CI: 1.29–3.71,  $p = 0.004$ ), micro-abscesses (adjusted OR 2.16 (95%CI: 1.22–3.83,  $p = 0.008$ ), the number of eosinophils and neutrophils  $\geq 150/\text{mm}^2$  (adjusted OR 0.97 (95%CI: 0.95–0.99,  $p = 0.013$ ), adjusted OR 3.04 (95%CI: 1.82–5.09,  $p < 0.001$ , respectively).

**Conclusions** These results corroborate the known clinical association of an appendicolith to complicated acute appendicitis.

**Keywords** Appendicitis · Complicated appendicitis · Appendicolith · Histopathology

**Electronic supplementary material** The online version of this article (<https://doi.org/10.1007/s00384-019-03332-z>) contains supplementary material, which is available to authorized users.

✉ Jari Mällinen  
jari.mallinen@gmail.com

<sup>1</sup> Department of Surgery, Oulu University Hospital, Oulu, Finland

<sup>2</sup> Division of Operative Care, Oulu University Hospital and Medical Research Center Oulu, University of Oulu, Oulu, Finland

<sup>3</sup> Cancer and Translational Medicine Research Unit, University of Oulu and Department of Pathology, Oulu University Hospital, Oulu, Finland

<sup>4</sup> Medical Research Center Oulu, Oulu, Finland

<sup>5</sup> Division of Digestive Surgery and Urology, Turku University Hospital, Turku, Finland

<sup>6</sup> Department of Surgery, University of Turku, Turku, Finland

<sup>7</sup> Satakunta Central Hospital, Pori, Finland

## Introduction

Acute appendicitis is one of the most common causes of abdominal pain in emergency departments. Acute uncomplicated and complicated appendicitis are epidemiologically and clinically different disease entities [1] also supporting the idea of a different pathophysiology and disease course. The majority (70–80%) of cases are uncomplicated. The incidence of uncomplicated acute appendicitis has been declining, whereas the incidence of complicated acute appendicitis has been quite steady over time [2].

Evidence from recent randomized trials [3–7] and meta-analyses [8–10] have shown that patients with uncomplicated acute appendicitis can be treated safely and efficiently with antibiotics. Our recent 5-year results further support the notion that antibiotic treatment alone is a safe alternative to appendectomy for uncomplicated acute appendicitis also at long-term follow-up [11]. In addition, antibiotic therapy for uncomplicated acute appendicitis is associated with significant cost savings [12] potentially having a major impact on overall health care costs based on the prevalence of acute appendicitis.

The presence of an appendicolith has been identified as an independent prognostic risk factor for treatment failure in non-operative treatment of uncomplicated acute appendicitis [13, 14], and it has also been shown to be associated with appendiceal perforation [15–17]. In the randomized study of Vons et al. [7] comparing antibiotic treatment with appendectomy in patients with computed tomography (CT)-verified uncomplicated appendicitis, patients presenting with an appendicolith were randomized and the presence of an appendicolith was associated with antibiotic treatment failure. Indeed, if they had excluded the patients with an appendicolith, no significant difference would have been found between the antibiotic treatment and appendectomy groups [7]. Despite these clinical findings indicating the important role of an appendicolith in developing of complicated acute appendicitis, little is known about possible histopathological differences between uncomplicated acute appendicitis and acute appendicitis presenting with an appendicolith, and the fecal material is often ignored in the process. The aim of our study was to assess these histopathological differences by using a prospective cohort including patients with either computed tomography (CT)-confirmed uncomplicated acute appendicitis enrolled in the surgical treatment arm of the randomized APPAC trial or patients with CT-verified complicated acute appendicitis presenting with an appendicolith excluded from the APPAC trial. This larger patient cohort was used previously in assessing the need for imaging in the differential diagnosis of uncomplicated and complicated acute appendicitis [18].

## Materials and methods

The present study is based on data from our randomized clinical APPAC trial designed to compare surgical and antibiotic

treatments for uncomplicated acute appendicitis. This current trial includes patients with either computed tomography (CT)-confirmed uncomplicated acute appendicitis enrolled in the surgical treatment arm of the randomized APPAC trial or patients with CT-verified complicated acute appendicitis presenting with an appendicolith excluded from the APPAC trial. The details of the APPAC trial protocol [19] and the 1- and 5-year results [4, 11] have been previously published. In the current study, we used the previously collected prospective patient cohort collected from the patients from the patients who underwent a CT scan performed according the APPAC trial protocol [19] from two largest participating hospitals (Turku University Hospital and Oulu University Hospital) in order to have a sufficient number of patients to assess possible histopathological differences between the groups.

Briefly, the initial APPAC trial is a multi-center, open-label, non-inferiority randomized controlled trial conducted from November 2009 to June 2012 in Finland at six Finnish hospitals (Turku, Oulu, and Tampere university hospitals and Jyväskylä, Mikkeli, and Seinäjoki central hospitals). The trial protocol was approved by the ethics committees of all participating hospitals, and all patients gave written informed consent to participate in the study. The trial involved 530 patients aged 18 to 60 years with CT-confirmed uncomplicated acute appendicitis. Patients with CT-confirmed uncomplicated acute appendicitis were randomized to either open appendectomy or antibiotic treatment with intravenous ertapenem (1 g once daily) for 3 days followed by 7 days of oral levofloxacin (500 mg once daily) and metronidazole (500 mg three times per day). CT criteria for acute appendicitis included appendiceal diameter exceeding 6 mm with wall thickening accompanied with at least one of the following features: abnormal contrast enhancement of the appendiceal wall, inflammatory edema, or fluid collections around the appendix. Exclusion criteria included complicated acute appendicitis (defined as the presence of an appendicolith, perforation, abscess, or suspicion of a tumor on the CT scan), age younger than 18 years or older than 60 years, contraindications for CT, peritonitis, inability to adhere with treatment and provide informed consent, and the presence of serious systemic illness. All the patients with an appendicolith at CT underwent appendectomy according to standard care. Patients in the antibiotic group were followed up by surgeons who could use their clinical judgment to pursue appendectomy, if considered necessary. Most of the treating surgeons were not part of the core study team and provided care according to their normal clinical practice. All antibiotic group patients with a clinical suspicion of recurrent appendicitis underwent appendectomy (Trial registration [clinicaltrials.gov](https://clinicaltrials.gov) NCT01022567).

In the present study, we compared the histopathological findings of the appendices removed either from patients with an uncomplicated acute appendicitis and randomized to appendectomy or the patients excluded from the study

undergoing appendectomy due to the presence of an appendicolith in the CT scan. The patients presenting with perforation or a periappendicular abscess in addition to the appendicolith were excluded from analysis. A total of 344 patients were included in this study. The uncomplicated acute appendicitis group consisted of 187 patients and there were 157 patients in appendicolith acute appendicitis group.

The formalin-fixed appendectomy specimens were processed at the pathology laboratory according to routine diagnostic practice of the two study hospitals. Samples were taken from appendiceal base, tip, most inflamed area, mesoappendix, and from any lesions observed in grossing. Five-micrometer-thick sections were cut from paraffin blocks, and subsequently stained with either van Gieson stain (Department of Pathology, Turku University Hospital) or with hematoxylin and eosin stain (Department of Pathology, Oulu University Hospital) according to hospital routine clinical staining practice. The slides were scanned with Aperio Image scanner and analyzed with Aperio Image Scope software, version 12.2.5015 (LeicaGmbH, Germany). The use of whole slide imaging enabled us to perform precise measurements and calculations that could be saved for later examination. The specimens were reviewed by a pathologist (MM), who was blinded for the clinical diagnosis and patient information. The following parameters were assessed: the appendiceal diameter, the depth of inflammation, mucosal damage, presence of microabscesses, the number of eosinophils and neutrophils in the appendiceal wall, and the presence of an appendicolith or residual fecal material, acknowledging that appendicolith presence may not be detected at histopathology examination as the appendicolith may be already discarded by the surgeon or pathologist when handling the specimen, i.e., the presence of an appendicolith inside the appendiceal lumen was always initially confirmed by a CT scan.

The maximum appendiceal diameter was measured from well representative cross sections, and this measurement was omitted, if there was any doubt on the reliability of the measurement, e.g., when only sections from the tip of the appendix or longitudinal sections were present. Because of tissue shrinkage in tissue processing, we did not attempt to correlate these diameters to the measured diameter at CT. The appendicolith was defined in the histopathological evaluation as a single concrement of fecal calcified material inside the appendiceal lumen. Any other luminal fecal material was recorded as such.

The acute inflammation was determined as the presence of edema, congestion, and emergence of inflammatory cells, mostly neutrophilic granulocytes. The radial depth of inflammation was measured from the surface epithelium towards the serosa. For classification purposes, surface epithelial damage, superficial necrosis, or ulceration was recorded as superficial mucosal damage and deeper mucosal inflammation involving

the crypts as deep mucosal damage. Micro-abscesses were defined as collections of neutrophilic granulocytes within the appendiceal wall without a direct luminal connection. The presence of micro-abscesses as well as their largest diameter was measured. The inflammatory cell count performed on predefined 0.100-mm<sup>2</sup> areas of dense inflammation, mostly in the inner muscular layer, where the cells were easily recognized, or occasionally in the submucosal layer, if the recognition was easier from there.

## Statistical analysis

Summary measurements are presented as mean with standard deviation (SD) unless otherwise stated. Between-group comparisons for continuous variables were performed with Student's *t* test or Welch *t* test, the latter if the variances differed significantly. Categorical variables were compared using Pearson  $\chi^2$  test or Fisher's exact test. Multivariate logistic regression models were created to assess the impact of each histopathologic parameters separately on acute appendicitis presenting with an appendicolith. The logistic regression models were adjusted with age, sex, and duration of symptoms. Odds ratios (OR) with 95% confidence intervals are presented as a result. Two-tailed *p* values < 0.05 are considered as statistically significant. Analyses were performed using SPSS for Windows (IBM Corp. Released 2018. IBM SPSS Statistics for Windows, Version 25.0. Armonk, NY: IBM Corp.).

## Results

The baseline patient demographics are presented in the Table 1 and characteristic histological features in Fig. 1. The results of the histopathological measurements are presented in detail in Table 2. The greatest appendiceal diameter was larger in appendicolith appendicitis specimens (9.181 mm vs 7.984 mm, *p* < 0.001). The diameter was not reliably measurable in 26.2% of uncomplicated and in 10.2% of appendicolith appendicitis specimens; these cases were excluded from the analysis. As in most cases, the inflammatory cell infiltration reached the serosa, the depth of inflammation was equal to the diameter of the appendiceal wall. In appendicolith appendices, the measurements were made from destroyed epithelial surface more often than in uncomplicated appendicitis specimens (47.7% vs 23.5%, respectively, *p* < 0.001). The inflammation in appendicolith appendices was less deep than in uncomplicated appendicitis (3.3 mm vs 3.6 mm, *p* < 0.001). Micro-abscesses were more prevalent in appendicolith appendicitis patients (27.3% vs 13.4%, *p* = 0.016). There was no difference in the size of the micro-abscesses between the two groups. Crypt destruction, characteristic of severe acute inflammation,

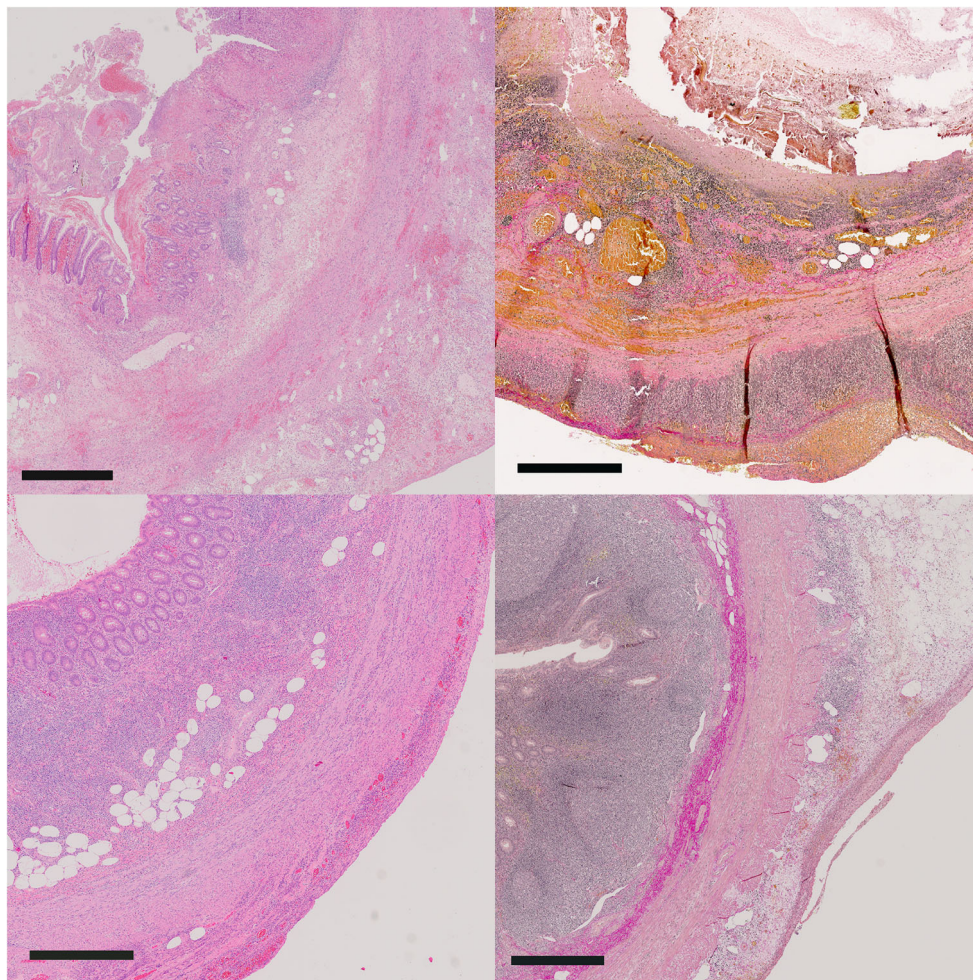
**Table 1** Baseline characteristics of the patients

	Uncomplicated acute appendicitis <i>n</i> = 187	Appendicolith appendicitis <i>n</i> = 157	<i>p</i> value
Male, <i>n</i> (%)	114 (51.4)	108 (48.6)	.14
Age, years, mean (SD)	35.3 (11.9)	35.1(12.9)	.73
CRP, mean (SD)	46.9 (43.7)	43.4 (50.7)	.61
WBC, mean (SD)	12.2 (3.9)	13.7 (3.5)	< .001
Duration of symptoms			.021
< 12 h, <i>n</i> (%)	32 (17.1)	44 (28.0)	
12–24 h, <i>n</i> (%)	46 (24.6)	44 (28.0)	
> 24 h, <i>n</i> (%)	106 (56.7)	69 (44.0)	

was more frequent in appendicolith appendices (49.0% vs 14.4%,  $p < 0.001$ ).

The neutrophilic granulocyte infiltration was more frequently dense in appendicolith appendicitis (42.7% vs 19.6%  $\geq 150/\text{mm}^2$ ,  $p < 0.001$ ), whereas the number of eosinophils was higher in uncomplicated acute appendicitis (11.0/ $\text{mm}^2$  vs 6.9/ $\text{mm}^2$ ,  $p = 0.001$ ). The value of 150 neutrophils/ $\text{mm}^2$  gave 80% specificity and therefore was used as a cut-off point. Next, we wanted to assess separately the impact of each histopathological parameter and created multivariable regression models for each individual histopathological parameter. The results of logistic regression analysis adjusting age, sex, and the duration of symptoms are shown in the Table 3.

Fecal material and appendicoliths were clearly associated CT-positive appendicolith appendicitis: appendicoliths were



**Fig. 1** Low-power views of complicated (upper row) and uncomplicated appendicitis (lower row). Upper left: a case of complicated acute appendicitis shows luminal fecal material, surface ulceration, and deep ulcer extending to muscular layer. Whole thickness of appendix is oedematous and congested, and mucosa is largely destructed (H&E, bar = 1 mm). Upper right: another case of complicated acute appendicitis shows luminal fecolith, and the mucosa is completely eroded. Submucosa and subserosa are filled with acute inflammatory cells, and there is fibrinopurulent material on the serosal surface (van

Gieson, bar = 0.6 mm). Lower left: a case of uncomplicated acute appendicitis shows preserved structures despite of transmural acute inflammation. Mucosal surface is preserved, and the submucosa is filled with inflammatory cells that extend to the muscular layers and serosa (H&E, bar = 0.7 mm). Lower right: another case of uncomplicated acute appendicitis shows prominent lymphoid follicles, and submucosal fibrosis (red). In muscle layer and subserosa, there is modest increase of inflammatory cells and edema (van Gieson, bar = 0.8 mm)

**Table 2** The histopathologic parameters measured

	Uncomplicated acute appendicitis, <i>n</i> = 187	Appendicolith appendicitis, <i>n</i> = 157	<i>p</i> value
Max diameter of appendix, mm, mean (SD), <i>n/N</i> (%)	7.954 (1.682)	9.181 (2.107)	< 0.001
Depth of inflammation, mm, mean (SD), <i>n/N</i> (%)	3.641 (1038)	3.325 (1001)	.007
≤ 2.8 mm, <i>n/N</i> (%)	165/187 (88.2)	145/157 (92.4)	.003
Superficial mucosal damage, <i>n/N</i> (%)	44/187 (23.5)	75/157 (47.7)	< 0.001
Deep mucosal damage, <i>n/N</i> (%)	27/187 (14.4)	77/157 (49.0)	< 0.001
Neutrophils, <i>n/mm</i> <sup>2</sup>			< 0.001
< 150, <i>n/N</i> (%)	144/179 (80.4)	82/143 (57.3)	
≥ 150, <i>n/N</i> (%)	35/179 (19.6)	61/143 (42.7)	
Eosinophils, <i>n/mm</i> <sup>2</sup> , mean (SD)	11.0 (14.5)	6.9 (9.8)	.001
Micro-abscesses			.016
No abscesses	162/187 (86.6)	119/156 (76.3)	
One or multiple abscesses	25/187(13.4)	37/156 (23.7)	
Presence of fecal material			< .001
No fecal material <i>n/N</i> (%)	155/187(82.9)	63/156 (40.4)	
Appendicolith <i>n/N</i> (%)	9/187(4.8)	26/156 (16.7)	
Fecal material	23/187(12.3)	67/156 (42.9)	

detected by pathologist in 16.7% of appendicolith appendicitis specimens and in 4.8% of the uncomplicated acute appendicitis patients. Similarly, residual fecal material was more prevalent in appendicolith appendicitis patients (42.9% vs 12.3%,  $p < 0.001$ ).

## Discussion

In this study comparing the histopathological findings of CT-verified uncomplicated acute appendicitis and complicated acute appendicitis presenting with an appendicolith, we showed significant histopathological differences between these two forms of acute appendicitis. Our results further corroborate the previous clinical findings showing that the presence of an appendicolith is an independent predictive factor for both perforation and the failure of non-operative treatment of uncomplicated acute appendicitis. This has been noted in two randomized clinical trials [4, 7] comparing appendectomy and antibiotic therapy using CT-confirmed diagnosis of

uncomplicated acute appendicitis as trial inclusion criteria. If Vons et al. [7] had excluded the patients with an appendicolith, no significant difference would have been found between the antibiotic and appendectomy group, and in the APPAC trial [19], the presence of an appendicolith was an exclusion criterion.

The different epidemiological trends of uncomplicated and complicated acute appendicitis indicate different pathophysiology [1]. Despite the high incidence of acute appendicitis, there are very few reports on appendicitis etiology and pathophysiology especially focusing on the possible differences between uncomplicated and complicated acute appendicitis. Appendicolith appendicitis is the most common form of complicated acute appendicitis recognized as such only during the last century [7, 13, 14] and the overall knowledge about appendicoliths or the underlying pathophysiology, microbiology, or the histopathological differences to uncomplicated acute appendicitis are very scarce. The exact pathogenesis of acute appendicitis is still unknown. During the last century, the presence of appendicoliths in acute appendicitis has been

**Table 3** The results of logistic regression analysis for the presence of acute appendicitis with appendicolith. The results are presented as odds ratio (OR) with 95% confidence interval (95% CI)

Variable	Univariate OR	Adjusted <sup>a</sup> OR	95% CI	<i>p</i> value
Micro-abscess	2.02	2.16	1.22 to 3.83	0.008
Eosinophils, <i>n/mm</i> <sup>2</sup>	0.97	0.97	0.95 to 0.99	0.013
Neutrophils, ≥ 150/ <i>mm</i> <sup>2</sup>	3.06	3.04	1.82 to 5.09	< 0.001
Fecal material	5.37	6.05	3.45 to 10.59	< 0.001
Depth of inflammation, ≤ 2.8 mm	2.17	2.18	1.29 to 3.71	0.004

<sup>a</sup> Adjusting variables age, sex, and duration of symptoms

reported mainly in small case series [20] until the last two decades showing the clinical association of appendicoliths to a more complicated course of the disease [7, 13, 14]. In 1960, Robert Carras recommended a prophylactic appendectomy to be considered if an appendicolith was visible in plain radiograph [21]. Already in 1966, Forbes and Lloyd-Davies proposed a classification for appendicoliths (fecoliths) according to the calcium they contained non-calcified fecal pellets, partially calcified fecoliths, and stony, fully calcified calculi [20]. They also recommended removal of the appendix, if an appendicolith was found incidentally on abdominal radiological examination as in their material, appendicolith was also associated with complicated appendicitis [20]. As a consequence of improved diagnostic imaging, especially computed tomography, we now know that an appendicolith may also be an incidental finding without any signs of appendicitis [22, 23] and when detected incidentally, does not increase the risk of developing appendicitis compared to the general population [24]. However, when presenting together with acute appendicitis, the presence of appendicoliths is associated with increased perforation risk and acts as an independent predictive factor for failure of non-operative management of appendicitis [7, 13–15, 25]. With the current available knowledge, the presence of an appendicolith in a patient with acute appendicitis should be classified as complicated appendicitis warranting emergency appendectomy and it is an exclusion criterion for non-operative management of acute appendicitis.

In our study, acute appendicitis presenting with an appendicolith was associated with shorter duration of symptoms and signs of more severe inflammation, such as mucosal ulcerations and micro-abscesses, than uncomplicated acute appendicitis (Table 2). In the former, appendiceal diameter was larger, the mucosa was more often ulcerated, and the appendiceal wall was thinner. This, together with the higher WBC count (Table 1), may reflect the more abrupt and complicated nature of acute appendicitis presenting with an appendicolith. There was no difference in CRP values between the study groups, which is in line with our previous study [18]. Alaedeen et al. showed that pediatric patients with an appendicolith had significantly higher CRP levels than those without an appendicolith [15]. This may reflect differences in acute phase reaction between children and adults.

Ishiyama et al. have investigated the significance of appendicoliths as an exacerbating factor of acute appendicitis with a special reference to the appendicolith location [26]. In their retrospective study, the appendicolith was diagnosed by a contrast-enhanced CT, and as all the patients underwent appendectomy, the diagnosis of non-gangrenous or gangrenous appendicitis was confirmed by a histopathological examination. In their study, both the size of appendicolith exceeding 5 mm and location at the root of the appendix were significantly associated with gangrenous appendicitis. On the other hand, there was a visible perforation in 27% of their cases of

gangrenous appendicitis, whereas in our study population, the perforated cases were excluded as we wanted to assess the histopathological differences between appendicolith appendicitis and uncomplicated acute appendicitis. A challenge of assessing the role of appendicoliths in acute appendicitis is the fact that the majority of appendicoliths are either removed or discarded during the handling of the appendiceal specimen by the surgeon. In our patient cohort of CT-verified appendicoliths, there was no fecal material found in 40% of the appendicolith appendicitis patients. In order to overcome this challenge of accurate and comprehensive assessment of the role of appendicoliths, we recommend that both surgeons and pathologists should document the appendicolith, and positive cases should be sampled to verify the process due to different etiology and possible differences in the outcomes of uncomplicated acute appendicitis and acute appendicitis presenting with an appendicolith. With the more comprehensive appendicolith data, it would be possible to assess the differences. The presence of fecal material in over 40% of remaining appendicolith patients probably represents a residual of appendicolith removed accidentally or incidentally. Within the appendicolith cases, i.e., in some cases of large appendicoliths, the obstruction leads to inflammation and eventually into perforation, whereas in the presence of softer material, inflammation leads gradually to obstruction.

In our study population, there was a significant difference in the number of neutrophils detected between uncomplicated and appendicolith appendicitis. Our result is equal to the finding in a recent study, where uncomplicated and complicated (gangrenous or perforated) appendicitis were compared in pediatric patient population [27]. As in our study, the perforated appendicitis cases were excluded, our result also reflects the complicated nature of appendicolith appendicitis. The number of eosinophils was significantly higher in uncomplicated acute appendicitis patients than in acute appendicitis presenting with an appendicolith. There is evidence suggesting that individual differences in immunological responses may explain part of the differences in the pathophysiology of uncomplicated and complicated appendicitis. The immune system is regulated by T-helper (Th) cells, which develop different immune responses according to different cell types, type 1 Th-cells (Th1) or type 2 Th-cells (Th2). Th1-cells induce activation of phagocytes and cytotoxic cells while Th2-cells induce secretion of antibodies and activation of mast cells, eosinophils and basophils [28]. According to previous studies, complicated appendicitis has been suggested to be associated to Th1-mediated immune response and uncomplicated appendicitis to Th2-mediated immune response [28, 29], and this is supported by the histopathological findings showing eosinophilic infiltration in resected appendices with uncomplicated appendices [30] as well as the detected eosinophilia in peripheral blood in pediatric patients with uncomplicated appendicitis [31, 32]. Our results are in accordance with previous studies and further

corroborate the classification of appendicolith appendicitis as complicated acute appendicitis.

The strengths of our study include the large prospective patient material with prospectively collected clinical data including patients with uncomplicated acute appendicitis enrolled in the randomized APPAC trial and the excluded appendicolith appendicitis patients [4, 33]. The second strong element of the trial is the availability of the CT-confirmed differential diagnosis between these two different forms of acute appendicitis combined with the histopathological confirmation of the diagnosis. Other strengths are the blinding of the appendiceal specimens for the histopathological assessment and the use of a single senior specialist in pathology (MM). Our study has several limitations. Firstly, it was somewhat limited by the retrospective study design despite the prospective data collection as for example, not all the appendicoliths detected at CT were available for histopathological assessment. We also included the patient data of only two study hospitals due to practical reasons of the number of specimens as in theory, this may lead to selection bias between the groups, but there was no difference in patient demographics between the groups.

In conclusion, our study showed that complicated appendicitis with an appendicolith and uncomplicated acute appendicitis differ from each other in their histopathology. Uncomplicated acute appendicitis less often manifests with microabscesses and mucosal damage, while complicated acute appendicitis with an appendicolith more often with these features. These differences may be related to the different outcome of uncomplicated acute appendicitis and complicated acute appendicitis with appendicolith. Our study gives a further support to the classification of appendicolith appendicitis as complicated acute appendicitis. Future studies including surgeons, pathologists, and microbiologists are needed to assess both the role of appendicoliths in appendicitis pathophysiology and etiology and also to evaluate the formation, microbiology, and classification of appendicoliths.

**Acknowledgments** The study was supported by government research grant awarded to Oulu University Hospital, Mary and Georg C. Ehrnrooth Foundation, The Instrumentarium Science Foundation and Finnish Medical Foundation. The authors wish to express their gratitude to Docent Jari Sundström (Department of Pathology, University of Turku, Turku, Finland) for his help in the material collection, and Docent Anne Tuomisto and Ms. Tarja Piispanen for their help on scanning the slides.

**Funding** Open access funding provided by University of Oulu including Oulu University Hospital. The study was supported by government research grant awarded to Oulu University Hospital, Mary and Georg C. Ehrnrooth Foundation, The Instrumentarium Science Foundation and Finnish Medical Foundation.

## Compliance with ethical standards

**Conflict of interest** The authors declare that they have no conflict of interest.

**Open Access** This article is distributed under the terms of the Creative Commons Attribution 4.0 International License (<http://creativecommons.org/licenses/by/4.0/>), which permits unrestricted use, distribution, and reproduction in any medium, provided you give appropriate credit to the original author(s) and the source, provide a link to the Creative Commons license, and indicate if changes were made.

## References

- Livingston EH, Fomby TB, Woodward WA, Haley RW (2011) Epidemiological similarities between appendicitis and diverticulitis suggesting a common underlying pathogenesis. *Arch Surg* 146: 308–314. <https://doi.org/10.1001/archsurg.2011.2>
- Livingston EH, Woodward WA, Sarosi GA, Haley RW (2007) Disconnect between incidence of nonperforated and perforated appendicitis: implications for pathophysiology and management. *Ann Surg* 245:886–892. <https://doi.org/10.1097/01.sla.0000256391.05233.aa>
- Hansson J, Korner U, Khorram-Manesh A, Solberg A, Lundholm K (2009) Randomized clinical trial of antibiotic therapy versus appendectomy as primary treatment of acute appendicitis in unselected patients. *Br J Surg* 96:473–481. <https://doi.org/10.1002/bjs.6482>
- Salminen P, Paajanen H, Rautio T, Nordstrom P, Aarnio M, Rantanen T, Tuominen R, Hurme S, Virtanen J, Mecklin JP, Sand J, Jartti A, Rinta-Kiikka I, Gronroos JM (2015) Antibiotic therapy vs appendectomy for treatment of uncomplicated acute appendicitis: the APPAC randomized clinical trial. *JAMA* 313:2340–2348. <https://doi.org/10.1001/jama.2015.6154>
- Svensson JF, Patkova B, Almstrom M, Naji H, Hall NJ, Eaton S, Pierro A, Wester T (2015) Nonoperative treatment with antibiotics versus surgery for acute nonperforated appendicitis in children: a pilot randomized controlled trial. *Ann Surg* 261:67–71. <https://doi.org/10.1097/SLA.0000000000000835>
- Styrud J, Eriksson S, Nilsson I, Ahlberg G, Haapaniemi S, Neovius G, Rex L, Badume I, Granstrom L (2006) Appendectomy versus antibiotic treatment in acute appendicitis. A prospective multicenter randomized controlled trial. *World J Surg* 30:1033–1037. <https://doi.org/10.1007/s00268-005-0304-6>
- Vons C, Barry C, Maitre S, Pautrat K, Leconte M, Costaglioli B, Karoui M, Alves A, Dousset B, Valleu P, Falissard B, Franco D (2011) Amoxicillin plus clavulanic acid versus appendectomy for treatment of acute uncomplicated appendicitis: an open-label, non-inferiority, randomised controlled trial. *Lancet* 377:1573–1579. [https://doi.org/10.1016/S0140-6736\(11\)60410-8](https://doi.org/10.1016/S0140-6736(11)60410-8)
- Harnoss JC, Zelenka I, Probst P, Grummich K, Muller-Lantzsch C, Harnoss JM, Ulrich A, Buchler MW, Diener MK (2017) Antibiotics versus surgical therapy for uncomplicated appendicitis: systematic review and meta-analysis of controlled trials (PROSPERO 2015: CRD42015016882). *Ann Surg* 265:889–900. doi: <https://doi.org/10.1097/SLA.0000000000002039>
- Poprom N, Numthavaj P, Wilarusmee C, Rattanasiri S, Attia J, McEvoy M, Thakkinstian A (2018) The efficacy of antibiotic treatment versus surgical treatment of uncomplicated acute appendicitis: systematic review and network meta-analysis of randomized controlled trial. *Am J Surg* (18):30954–30951. <https://doi.org/10.1016/j.amjsurg.2018.10.009>.doi:S0002-9610
- Sallinen V, Akl EA, You JJ, Agarwal A, Shoucair S, Vandvik PO, Agoritsas T, Heels-Ansdell D, Guyatt GH, Tikkinen KA (2016) Meta-analysis of antibiotics versus appendectomy for non-perforated acute appendicitis. *Br J Surg* 103:656–667. <https://doi.org/10.1002/bjs.10147>

11. Salminen P, Tuominen R, Paajanen H, Rautio T, Nordstrom P, Aarnio M, Rantanen T, Hurme S, Mecklin JP, Sand J, Virtanen J, Jartti A, Gronroos JM (2018) Five-year follow-up of antibiotic therapy for uncomplicated acute appendicitis in the APPAC randomized clinical trial. *JAMA* 320:1259–1265. <https://doi.org/10.1001/jama.2018.13201>
12. Sippola S, Gronroos J, Tuominen R, Paajanen H, Rautio T, Nordstrom P, Aarnio M, Rantanen T, Hurme S, Salminen P (2017) Economic evaluation of antibiotic therapy versus appendectomy for the treatment of uncomplicated acute appendicitis from the APPAC randomized clinical trial. *Br J Surg* 104:1355–1361. <https://doi.org/10.1002/bjs.10575>
13. Mahida JB, Lodwick DL, Nacion KM, Sulkowski JP, Leonhart KL, Cooper JN, Ambeba EJ, Deans KJ, Minneci PC (2016) High failure rate of nonoperative management of acute appendicitis with an appendicolith in children. *J Pediatr Surg* 51:908–911. <https://doi.org/10.1016/j.jpedsurg.2016.02.056>
14. Shindoh J, Niwa H, Kawai K, Ohata K, Ishihara Y, Takabayashi N, Kobayashi R, Hiramatsu T (2010) Predictive factors for negative outcomes in initial non-operative management of suspected appendicitis. *J Gastrointest Surg* 14:309–314. <https://doi.org/10.1007/s11605-009-1094-1>
15. Alaedein DI, Cook M, Chwals WJ (2008) Appendiceal fecalith is associated with early perforation in pediatric patients. *J Pediatr Surg* 43:889–892. <https://doi.org/10.1016/j.jpedsurg.2007.12.034>
16. Singh JP, Mariadason JG (2013) Role of the faecolith in modern-day appendicitis. *Ann R Coll Surg Engl* 95:48–51. <https://doi.org/10.1308/003588413X13511609954851>
17. Yoon HM, Kim JH, Lee JS, Ryu JM, Kim DY, Lee JY (2018) Pediatric appendicitis with appendicolith often presents with prolonged abdominal pain and a high risk of perforation. *World J Pediatr* 14:184–190. <https://doi.org/10.1007/s12519-018-0128-8>
18. Lietzen E, Mallinen J, Gronroos JM, Rautio T, Paajanen H, Nordstrom P, Aarnio M, Rantanen T, Sand J, Mecklin JP, Jartti A, Virtanen J, Ohtonen P, Salminen P (2016) Is preoperative distinction between complicated and uncomplicated acute appendicitis feasible without imaging? *160:789–795*. doi: <https://doi.org/10.1016/j.surg.2016.04.021>
19. Paajanen H, Gronroos JM, Rautio T, Nordstrom P, Aarnio M, Rantanen T, Hurme S, Dean K, Jartti A, Mecklin JP, Sand J, Salminen P (2013) A prospective randomized controlled multicenter trial comparing antibiotic therapy with appendectomy in the treatment of uncomplicated acute appendicitis (APPAC trial). *BMC Surg* 13:3. <https://doi.org/10.1186/1471-2482-13-3>
20. Forbes GB, Lloyd-Davies RW (1966) Calculous disease of the vermiform appendix. *PMCID* 7:583–592
21. Carras R, Friedenber MJ (1960) A clinical and radiographic study of appendiceal fecaliths: a review of the literature and report of seven cases. *Ann Surg* 151:374–378
22. Huwart L, El Khoury M, Lesavre A, Phan C, Rangheard AS, Bessoud B, Menu Y (2006) Is appendicolith a reliable sign for acute appendicitis at MDCT? *J Radiol* 87:383–387
23. Jones BA, Demetriades D, Segal I, Burkitt DP (1985) The prevalence of appendiceal fecaliths in patients with and without appendicitis. A comparative study from Canada and South Africa. *Ann Surg* 202:80–82
24. Khan MS, Chaudhry MBH, Shahzad N, Tariq M, Memon WA, Alvi AR (2018) Risk of appendicitis in patients with incidentally discovered appendicoliths. *J Surg Res* 221:84–87
25. Aprahamian CJ, Barnhart DC, Bledsoe SE, Vaid Y, Harmon CM (2007) Failure in the nonoperative management of pediatric ruptured appendicitis: predictors and consequences. *J Pediatr Surg* 42:8
26. Ishiyama M, Yanase F, Taketa T, Makidono A, Suzuki K, Omata F, Saida Y (2013) Significance of size and location of appendicoliths as exacerbating factor of acute appendicitis. *Emerg Radiol* 20:125–130. <https://doi.org/10.1007/s10140-012-1093-5>
27. Gorter RR, Wassenaar ECE, de Boer OJ, Bakx R, Roelofs JJTH, Bunders MJ, van Heurn LWE, Heij HA (2017) Composition of the cellular infiltrate in patients with simple and complex appendicitis. *J Surg Res* 214:190–196 doi: **S0022-4804(17)30112-9 [pii]**
28. Ruber M, Berg A, Ekerfelt C, Olaison G, Andersson RE (2006) Different cytokine profiles in patients with a history of gangrenous or phlegmonous appendicitis. *Clin Exp Immunol* 143:117–124 doi: **CEI2957 [pii]**
29. Ruber M, Andersson M, Petersson BF, Olaison G, Andersson RE, Ekerfelt C (2010) Systemic Th17-like cytokine pattern in gangrenous appendicitis but not in phlegmonous appendicitis 147:366–372. doi: <https://doi.org/10.1016/j.surg.2009.09.039>
30. Yaeger AA, Cheng PM, Tatishchev S, Whang G (2018) Acute eosinophilic appendicitis: a radiologic-pathologic correlation. *Clin Imaging* 51:337–340
31. Minderjahn MI, Schadlich D, Radtke J, Rothe K, Reismann M (2018) Phlegmonous appendicitis in children is characterized by eosinophilia in white blood cell counts. *World J Pediatr* 14:504–509. doi: <https://doi.org/10.1007/s12519-018-0173-3>
32. Reismann J, Schadlich D, Minderjahn MI, Rothe K, Reismann M (2019) Eosinophilia in pediatric uncomplicated appendicitis is a time stable pattern. *Pediatr Surg Int* 35:335–340. <https://doi.org/10.1007/s00383-018-4423-1>
33. Salminen P, Tuominen R, Paajanen H, Rautio T, Nordstrom P, Aarnio M, Rantanen T, Hurme S, Mecklin JP, Sand J, Virtanen J, Jartti A, Gronroos JM (2018) Five-year follow-up of antibiotic therapy for uncomplicated acute appendicitis in the APPAC randomized clinical trial. *JAMA* 320:1259–1265. <https://doi.org/10.1001/jama.2018.13201>

**Publisher's note** Springer Nature remains neutral with regard to jurisdictional claims in published maps and institutional affiliations.