

From Bones to Sacred Artefact: The Late Medieval Skull Relic of Turku Cathedral, Finland¹

AKI ARPONEN

University of Turku

HELI MAIJANEN

University of Oulu

VISA IMMONEN

University of Turku

Abstract

The cult of saints and the subsequent interest in relics constituted one of the essential characteristics of medieval Western Christianity. In particular, relics and reliquaries are prime examples of the importance of materiality in devotion. In the present article we analyse one of the medieval skull relics of Turku Cathedral and its material characteristics in detail. Previous examinations undertaken in the 1920s and 1940s produced two theories of its origins and identification. By analysing the bone material and the narrative depiction of martyrdom embroidered on the silk wrapping, State Archaeologist Juhani Rinne connected the relic to St Henry, the patron saint of Finland and the cathedral, while State Archaeologist Carl Axel Nordman identified it as belonging to St Eric, the patron saint of the Kingdom of Sweden. By re-examining the central element of the skull relic, the bones, with osteological analysis and radiocarbon dating, we show both theories to be highly problematic. Our analysis reveals the complex material features of the skull relic and the medieval cult of relics.

Keywords: skull relic, Middle Ages, Turku Cathedral, Christian relic cult, osteological analysis, interdisciplinary

The late medieval relics and reliquaries of Western Christianity are prime examples of the importance of materiality in devotion (Bynum 2011). Some reliquaries are simple products, consisting of a bone fragment placed inside folded sheets of lead, while others are highly complex objects incorporat-

¹ This research was supported by the Eino Jutikkala Fund of the Finnish Academy of Science and Letters and the Jenny and Antti Wihuri Foundation.

ing numerous human remains and other artefacts covered with layers of textiles and precious metals. However, to speak of their materiality refers not only to the characteristics of individual bone fragments and other sacred pieces and the concrete materials and tools used in production, but also the production techniques, the organisation of labour, the provenance of various materials, devotional practices, and even more abstract conceptions of the presence of the sacred in the matter (Bagnoli et al. 2011; Robinson et al. 2014). An analysis of the intricate material nature and construction of relics and reliquaries is therefore pivotal for an understanding of the character of devotional objects and the medieval cult of relics.

The study of the materiality of relics is especially important in cases where only scant or no written evidence on the objects survives. A case in point is the skull relic at Turku Cathedral (Fig. 1), which has no textual information on its identity, origins, or age. Until the 1920s the skull relic was kept in a wooden construction called the shrine of Blessed Hemming, and the skull was therefore considered to belong to Bishop Hemming (c. 1290–1366; Lindman 1869, 28). He was the Bishop of Turku between 1338 and 1366 and was beatified in Turku Cathedral in 1514.

The object had already attracted a scientific study in the 1920s, when the earliest scholarly examination of the cathedral's relic collection took place. The pioneering work was done by State Archaeologist Juhani Rinne (1872–1950), who presented the first interpretation of the identity and history of the skull relic (Rinne 1932). In the 1950s State Archaeologist Carl Axel Nordman (1892–1972) introduced another interpretation (Nordman 1954). The conflicting theories formed the background for a new research of the skull relic in 2011. This was part of the research project on the relics and reliquaries of Turku Cathedral Professor Emeritus Jussi-Pekka Taavitsainen has directed since 2007 (Taavitsainen 2011).

Already in the early stages of dismantling the object and receiving the first results of the scientific analyses, the skull relic proved a considerably more intricate object than Rinne and Nordman had imagined. This raises a series of questions. What is the importance of natural scientific methods in approaching devotional objects, and has their application changed our understanding of the cult of relics during the 20th and 21st centuries? How can their results be combined with the humanities approach? In the present article we seek answers to these questions, first, by sketching an outline of the cult of relics. We then describe the construction of the skull relic of Turku, starting with textiles used in the skull relic, their scientific dates, and techniques of production; we proceed to an osteological analysis of the

bones. The development of new scientific methods has radically modified and complicated the interpretation of the skull relic in Turku. The variety of scientific analyses of the sacred artefact has revealed medieval attitudes towards relics and devotional objects.

The emergence of the medieval cult of relics

The centrality of relics is not unique to Catholic Christianity. Indeed, albeit to differing degrees of importance, many major world religions – including Buddhism, Hinduism, and Islam – have traditions of venerating the earthly remains of holy persons or objects that have been in contact with them (Strong 2007; Meri 2010; Aymard 2014; Hooper 2014). However, since the 1980s the cult of saints has come to be seen as one of the most characteristic aspects of medieval Western Christianity (Bynum & Gerson 1997, 3f.). Relics and reliquaries were at the core of medieval piety, and the cult of saints spread throughout society (George 2013).

Caroline Walker Bynum (1995; 2002) points out the gradually increasing interest in body parts as objects of veneration during the Middle Ages. The cult was based on the bible. Luke writes of those strong in faith: ‘Not a hair of your head shall perish’ (Luke 21:18). According to the Pauline view all Christians are ‘saints’, because they have entered more fully into the life of Christ by death (Ward 2010, 275). The physical remains of certain Christians who had shown special signs of the Holy Spirit in life and death were held in unique honour. Based on the creation of the whole person in the image of God, there was no reason to think their flesh was less holy after death.

In the fourth century Cyril of Jerusalem (c. 313–386) taught in his catechetical lectures that ‘there reposes in that body a power greater than that of the soul itself, the grace of the Holy Spirit’ (Ward 2010, 275). Due to the dramatic expansion of the church in Late Antiquity, most new Christians lived far away from the graves of the early martyrs. Subsequently, the bones of martyrs began to be transported to urban basilicas. They were placed under the altars so the mysteries were always celebrated in the presence of the saints (Angenendt 2007, 167–72). An increasing number of holy bodies were broken up and the pieces sent to new Christian groups.

As the size of relics decreased, their mobility increased. They could be carried around in processions and moved between places and churches, and some relics entered private possession (Bartlett 2013, 275). Relics also moved people, because the devotee needed physical contact with the most important remains of holy persons (Geary 1986, 179; Ward 2010, 277). This

was the motivation for medieval pilgrimages, the cities of Jerusalem, Rome, and Santiago de Compostela being the most famous destinations, although there were hundreds of pilgrim sites to visit across Europe. Relics, especially famous ones, enhanced the spiritual capital of churches and brought them visitors, donations, and financial benefits.

The ongoing fragmentation of relics was a concern, and Theodoret of Cyrus (393–c. 458/466) stated that ‘when the body is divided, the grace remains undivided’ (Miller 2009, 199). In other words, even the tiniest piece of a holy person had the saint’s miraculous presence in full. The theme of relics’ miniscule and nondescript actuality, however, remained a cause of anxiety, and in the 12th century the Benedictine abbot Peter the Venerable (1092–1156) argued that the relics of the saints were already their resurrected bodies (Bynum 2002, 15). Accordingly, one should not feel contempt for the bones of the present martyrs, but honour them as now full of life, as if they were in their future incorruptible state.

The authentication of a body part as a holy relic was an issue that frequently preoccupied medieval clergy and laymen. Patrick Geary (1986, 175f.) identifies three interrelated beliefs required for the communal acceptance of relics. First, during the saint’s life and after her or his death the individual had to have a special connection with God manifested through her or his actions. Second, the church had to officially authenticate the corpse or its part as belonging to a particular saint. Third, the remains of such a person were to be prized and treated in a special way.

The recognition of a relic involved a formal ceremony called an *inventio*. It was carried out by assessing the relic candidate and evaluating whether it met the extrinsic and intrinsic standards for a true relic (Geary 1986, 176). The extrinsic criteria entailed the formal processes of investigating the tomb or reliquary and an examination of *authenticae* documents. These are slips of parchment attached to the relics with inscriptions indicating their identities. Internal criteria denoted the miracles the saint performed after their death. The saint usually indicated where the body parts were to be found, and during the authentication process the holy person showed through supernatural intervention that the remains were indeed genuine. If its results were affirmative, the relic was presented for public veneration in a ritual known as an *elevatio*, and when the relic was moved from one location to another, a *translatio* took place involving a series of formal ceremonies and possibly a procession (Angenendt 2007, 172–75).

By the late Middle Ages it had become church law that relics must be used in the consecration of a church and placed permanently beneath its

altars. The law emphasised that 'the relic should be of a size sufficient for them to be recognized as parts of human bodies; very small relics may not be used' (Nafte 2015, 212). Because of their relatively wide availability and the possibility of creating new relics by dividing older ones, churches gathered dozens if not hundreds of relics, including the relics of the saint to which the building was consecrated. In 1215, alongside their vital presence in churches, the Fourth Lateran Council decreed that relics were not to be displayed outside their containers (Montgomery 2010, 60; Bartlett 2013, 305). In effect reliquaries were like an epidermal layer over the saint's actual body and kept the precious small pieces together and safe.

The dynamics of relics and reliquaries

The distinction between relics and reliquaries seems unequivocal. However, in the Middle Ages their relationship was complex in terms of both theology and material culture. As Cynthia Hahn (2017) points out, a reliquary is akin to a gift box. As it performs its function of presentation, the reliquary is erased in the presence of the relic. Precisely as the medieval reliquary is materiality glorified, sparkling silver, gold, and gems, it simultaneously denies its own existence, standing only as a setting or context for the staging of the relic. If a relic were an object that prompted an intense human response, the function of its reliquary was to open a space for the imagination to be filled with devotion.

A preference for certain parts of the body is visible in the surviving 'speaking reliquaries' (Bynum & Gerson 1997). These are metal containers which express the body part underneath. The most popular were heads and arms, the most expressive and communicative parts of human bodies. However, many of the body-part reliquaries did not actually contain the body part they seemed to imitate, but they could instead house the relics of several saints. Consequently, the shape of body-part reliquaries depended more on the referentiality of body parts and the function of the reliquary than on its contents.

Not all reliquaries were shaped like body parts (Braun 1940). The largest were caskets which look like miniature versions of buildings. Another common type of reliquary borrowed its shape and ornamentation from liturgical vessels like chalices and monstrances. Altar and processional crosses mounted with relics were also typical reliquaries, but even ecclesiastical objects like wooden sculptures could have relics incorporated into them. Small reliquary crosses and other reliquary pendants could also be privately owned and worn as dress accessories.

The complex relationship between relics and reliquaries is manifested in the many material layers surrounding medieval relics. There was rarely only one relic, a piece of bone, inside one container: usually, there were a number of reliquaries inside each other. In some sense the church building as such was a reliquary protecting the relics it housed. Many smaller reliquaries were shaped like ecclesiastical buildings, repeating the architecture which contained them. Inside a church reliquaries were stored and displayed in a particular architectural setting such as a dedicated chapel or a niche in the wall. The altar functioned as a reliquary for the relics it contained.

Even genuine medieval reliquaries have several layers before the actual relic is reached. For example, a head reliquary might have an outer surface moulded in gilded silver and placed on a wooden core. This core in turn had a small cavity containing the relic. A relic, whether a fragment of bone, textile, or other material, was often protected by a linen cloth and wrapped in a piece of sumptuous fabric. The package was then furnished with an authentication slip. In addition to reliquaries placed inside one another, in some cases the reliquary concretely structured its relics into a recognisable entity. This is most evident with some skull reliquaries.

Three skull relics at Turku Cathedral

Skull relics were a popular item in the medieval cult of relics. They consist of a human cranium wrapped in textiles or placed in containers of wood or precious metal. Occasionally, skull reliquaries do not include an entire skull but a scattered group of bones that may originate from one or several human crania. The collection of medieval relics at Turku Cathedral includes three skull reliquaries. Unfortunately, they all lack *authenticae* and thus cannot be directly associated with any known saint or cult. All information has to be extracted from the objects themselves with the assistance of art history and the sciences.

In the 1920s Rinne examined all the relic material at Turku Cathedral. He was a pioneer in combining scientific analyses with medieval hagiographical evidence, church history, and the architectural history of the cathedral. The two scientific methods Rinne applied were radiography and anatomical examination. The latter analysis was conducted by the professor of anatomy Yrjö Kajava (1884–1929) of the University of Helsinki. Since none of the reliquaries were opened, he could do a hands-on examination only of individual, unwrapped bones in the collection. Kajava's analysis of the bones inside reliquaries was therefore based solely on radiographs.

When Rinne (1932) presented his identification of the three skull relics, he emphasised first, the particular features of their textile wrappings, and second, the location in which they were kept after the Reformation. The pool Rinne considered as possibly connected with the skull relics was limited to Nordic saints. However, in addition to the Nordic alternatives a number of other saints with altars at the cathedral could have been considered.

The first of the skull relics of Turku Cathedral was found in a bricked-up niche inside the sacristy in 1924. In addition to a cranium the niche revealed two arm bones which are currently missing and silk covers for both the cranium and arm bones. Rinne suggests that these bones belong to the patron saint of Finland, St Henry of Uppsala (died c. 1156), because they were kept safe inside the wall. St Henry was the Bishop of Uppsala, who arrived in Finland in a crusade and converted the population to Christianity in the 1150s (Heikkilä 2005). He was then murdered by the Finnish farmer Lalli (Taavitsainen, Oinonen, & Possnert 2015).

The two other skull relics were deposited in a medieval wooden casket known as the shrine of Blessed Hemming. The first of the skull relics is wrapped in a hemispheric textile cover. This reliquary contains small pieces of bone placed in linen packages attached to a large piece of cloth. The reliquary has a cross-shaped motif on its top, based on which Rinne interpreted the object as the cap of St Bridget of Sweden (1303–1373; Karttala 2014). In addition to the purported cap of St Bridget the shrine of Blessed Hemming included another skull relic, which is the focus of this paper (Arponen 2015).

Kajava's examination of the skull relic wrapped in red silk damask

The skull relic wrapped in red silk damask is similar in size to an average adult cranium. It is 19.2 cm long, 14.1 cm wide, and 12 cm high. The object can be divided in two: a textile reliquary and an artificial skull structure. The textile reliquary consists of three layers of fabric. The innermost layer is made of linen, whereas the two outer layers are of silk. On the surface of the topmost silk, a red damask cloth, a pictorial motif of a martyrdom has been embroidered with silk and metal threads.

The skull structure consists of bones deposited in linen packages which have been sewn together with a thread of linen (Fig. 2). The largest bones are placed in roughly the same locations as they would be in a real human cranium. In front of the skull structure there is a large hole which approximately corresponds to the area in the human face between the mandible and

frontal bone. The structure is so densely packed that no additional material support was needed.

In his anatomical report Kajava notes that even by looking at the skull relic it was clear it could not contain an actual cranium. He could tell that the relic consisted of multiple separate bones by feeling it through the fabric. The mandible was easily identified through the textile, and he could make observations on the cranial bone on the top of the relic through a hole in the fabric. The rest of his observations were based on radiographs. Kajava (1932, 340, 344) states that other bones were included in the relic in addition to the cranial bones, some of which may have been animal bones.

Kajava (1932, 340) describes the mandible as gracile with a narrow but protruding chin. He notes a fracture on the left side of the mandible, which had probably occurred after the relic had been assembled. The measurements of the mandible suggest that it was of the same size as the cranium found in the sacristy of Turku Cathedral (Kajava 1932, 345). The mandible had sockets for all the teeth, but the third molars had not formed at all. The radiographs showed that there were some tooth roots present in their sockets, including the left second premolar and right first molar. The rest of the teeth had probably fallen out or been removed after death. The relic also had a tooth in a separate package that was placed where the maxillary teeth would have been. Based on the shape of the tooth, Kajava (1932, 342) suggests that it was probably a lower second premolar. An opening in the fabric wrapping exposed a hole in the right parietal. Kajava (1932, 337) notes that there were carving marks on one of the margins of the hole. The depression next to the hole seems to have been the result of some kind of pressing force. He presents no interpretation of the purpose or the timing of the perforation.

From the radiographs Kajava identifies occipital and parietal bones, which form the top and the back of the cranium. The fact that the suture between the parietal bones was partly open indicated that the deceased was under forty years old (Kajava 1932, 344). This relatively young age was supported by the fact that the individual had lost no teeth. Hence, Kajava concludes, the relic cannot belong to Bishop Hemming, as he was seventy-six at the time of his death in 1366.

Rinne's interpretation

Rinne constructed his identification of the skull relic on the depiction of a martyrdom embroidered on the surface of the reliquary (Fig. 3). It represents

a man in knight's armour with a raised sword. A headless man wearing a long vestment is kneeling and holding his hands in prayer. His severed head lies on the ground between the two men. Rinne (1932, 347f.) dated the knight's surcoat to the turn of the 13th and 14th centuries by comparing the scene with, for example, a depiction on Birger Persson's sepulchral monument from the 1310s at Uppsala Cathedral. Rinne also considers the shape of the knight's sword to date it to the beginning of the 14th century. This early dating and the fact that Bishop Hemming was not a martyr leads Rinne to abandon the idea that the skull relic belonged to him.

As with Kajava's observation that the dimensions of the mandible in the skull relic fitted those of the cranium found in the sacristy niche, Rinne associated them with each other. Moreover, he assumed that the cranium and the arm bones in the niche were St Henry's. It was therefore logical to identify the mandible as belonging to the patron saint of Finland. Since Rinne (1932, 354) considered the mandible to form the core of the skull relic, he did not hesitate to attribute the entire skull relic to St Henry.

Rinne's attempt to support his identification through embroidery analysis is unconvincing. The only element which ties the scene of the martyrdom to St Henry are the martyr's shoes. Rinne suggests, on very shaky grounds, that they were episcopal sandals. A more serious problem with Rinne's argumentation is the apparent disparity between the weapon used to decapitate the martyr on the embroidery, a sword, and the weapon mentioned in St Henry's hagiography, an axe. Rinne explains this discrepancy by suggesting the embroidery was a representation of St Henry's martyrdom based on an older tradition in which the weapon of slaughter was a sword. Rinne even tries to support this idea by pointing to a 16th-century Italian drawing of St Henry's murder. It was drawn by the Italian Niccolò Circignani (born c. 1517/1524, died after 1596) and published as gravures in Bartholomeus Grassi's *Ecclesiae anglicanae trophæa* (1584). However, in Circignani's drawing St Henry is not murdered with a sword but with a dagger.

Nordman's new attribution

Another important saint for the Diocese of Turku in addition to St Henry of Uppsala was King Eric IX of Sweden, who accompanied St Henry to Finland. The patron saint of Sweden was martyred in 1160, and his remains were deposited in a reliquary at Uppsala Cathedral. The contents of the reliquary were examined in the 1940s, and this gave Carl Axel Nordman a basis for a new interpretation of the skull relic in Turku.

As part of the 1940s examination the mandible of the skull relic was taken to Uppsala for anatomical analyses. It was also fitted to the supposed cranium of St Eric. Nordman (1954) refutes Rinne's assumption of the link between the skull relic and St Henry. First, according to Nordman, the footwear of the martyr depicted on the embroidery was not proof of his status. Nothing in the martyr's dress suggests that he was a bishop. Indeed, in religious art between the 13th and 16th centuries both the Apostles and holy kings wear similar robes reaching to the ground. Second, Nordman rejects Rinne's theory of a nobleman killing St Henry with a sword. Nordman points out that the legend of St Henry, the later folklore, and the tradition passed on by the modern historians give no indication of the weapon being a sword. Third, Nordman argues that the early modern draft by Circignani is much too late to provide evidence of earlier conventions of art (Nordman 1954, 308, 311). In medieval art St Henry's martyrdom was always staged with an axe.

Nordman presents an alternative interpretation of the skull relic's identity. He bases it on the hypothesis that the martyr represented on the reliquary is either a layperson or a clergyman. This involves dozens of decapitated medieval saints, and Nordman thus limits the number of potential candidates by assuming that the skull relic was so valuable that the saint must have been relatively highly respected at Turku Cathedral. Nordman could think of no other holy man except St Eric as the saint represented in the embroidered scene. He admits, however, that there are some iconographic differences between the martyr on the embroidery and the medieval sculptures of St Eric. Nevertheless, of all the saints murdered with a sword St Eric was the only one whose feast was ranked at the highest level, *totum duplex*, in the calendars of saints of the Diocese of Turku. Nordman suggests another possibility for identification as well – St Paul – but he rejects this interpretation for an obscure reason: St Paul and St Peter shared the same feast day. Moreover, St Eric was already one of the patron saints of Turku Cathedral by 1400, supporting the attribution of the sumptuous reliquary to him. Nordman (1954, 311) concludes by identifying the skull relic as St Eric's and suggests that it was made in Uppsala.

Nordman attempts to support his theory with the anatomical analyses conducted by Dr Bo E. Ingelmark in the 1940s. He compares the mandible of the skull relic with the cranium found in the sacristy niche. Ingelmark concludes that the cranium and the mandible do not belong to the same person because the tooth sockets in the maxilla show pathological changes which are not observed in the mandible. Since Nordman (1954, 309ff.) as-

sumes that the cranium was St Henry's, the anatomical analysis proves that the mandible and, consequently, the skull relic as a whole could not be linked to him. Unfortunately, the maxilla of the cranium is now missing, preventing any comprehensive re-examination.

Based on similar dimensions the mandible of the skull relic in Turku was fitted to the cranium in the reliquary of St Eric at Uppsala Cathedral. After closer examination Ingelmark writes that the cranium was bigger than the mandible, and concludes that the cranium was masculine, whereas the mandible was gracile. Hence, it was likely that the bones were not from the same individual (Ingelmark 1954, 254–255). To explain the unfavourable results of the anatomical examination, Nordman claims that by the time the skull relic of Turku was assembled the mandible was interpreted as belonging to St Eric, despite its possible female origin (Nordman 1954, 313, 317).

In addition to his observations on the cranium Ingelmark (1954, 254) reports that the tooth Kajava had identified as a lower second premolar is actually a deciduous canine tooth. Moreover, Ingelmark observes a loose tooth root near the fracture site. It is probably the root of the left second premolar that Kajava had seen in the X-ray of the mandible. Ingelmark (1954, 254) interprets the fracture as having occurred around or after the time of death.

Nordman's dating of the skull relic differs considerably from Rinne's, because he emphasises the difference between the dating of the embroidery on the silk and the actual assembling of the skull relic. Nordman suggests that the depiction was embroidered in Uppsala around 1300 or slightly earlier, and the silk was then used as a wrapping for one of the relics of St Eric. Around 1400 the silk was re-used as a cover for the newly constructed skull relic, which was soon given to Turku Cathedral where a new altar had been founded and dedicated to Saints Eric and Henry (Nordman 1954, 317f.). Nordman's theory of St Eric's skull relic has been repeated in several subsequent publications (e.g. Pykkänen 1976, no. 29; Riska 1987, 252f.; Gardberg et al. 2000, 276).

New discoveries

The skull relic was disassembled in 2010–2011. On the one hand this was the only way to document the artefact in detail and obtain the necessary samples for scientific analyses. On the other the condition of the skull relic was deteriorating because it had been tampered with several times. In the first photographs taken of the skull relic before Rinne's examinations the

textile covers of the upper part of the skull relic were opened, revealing the bones of the vertex. There was also a long tear on the left side of the skull relic, indicating a violent opening of the textile covers.

In the 1920s the skull relic was conserved for the first time. A piece of cardboard was placed on the reliquary's base. It formed a platform for iron wires which were used to reinforce the skull construction inside. Even some plastic materials were added to support the textile covers. In the 1940s the skull relic was opened, and the mandible was taken out for examination. On this occasion the supporting structure was destroyed by cutting the iron wires. However, while the skull relic was eventually closed and the dismantled stitches replaced with new ones, the damaged supporting structure of iron wires was left in place. This incomplete conservation work meant that the structure of the skull relic started to deteriorate, wrinkles emerged in the textile covers, and the lowest part of the embroidery was bent under the base of the reliquary. To improve the disposition of the skull relic, a complete re-conservation was required. This would include the removal of the remains of the iron wires and other modern materials, and creating a new support inside the skull relic.

Since the opening of a skull relic is an extremely rare event, every effort was taken to carry out the process carefully and document any and all steps. Several samples were extracted to obtain reliable results for the dating and identification of the origins of the materials. All the bones were also osteologically analysed. The materials and the weave or twist of most of the fabrics and threads in the skull relic were examined. Samples for dye analysis from two of the three coloured textiles were also taken and analysed at the textile laboratory of the Royal Institute for Cultural Heritage (KIK-IRPA) in Brussels (Vanden Berghe 2016). By March 2017 forty-six radiocarbon-dating results had been obtained: fifteen were from bones and thirty from fabrics and threads. The dating results include one sample from a grain found between the layers of cloth in the skull relic.

The date of construction

Rinne and Nordman had no access to natural scientific means to date the skull relic. However, textile research and iconographic analysis provided them with clues to the age of the materials. By comparing stylistic details, Rinne dated the embroidered scene of the martyrdom to the beginning of the 14th century, and his conclusions still seem valid. The style of the knight's long and loose surcoat was not favoured after the mid-14th cen-

ture (Fig. 4; e.g. Houston 1996; Newton 2002; Scott 2007). The radiocarbon dating result of a thread in the embroidery supports Rinne's iconographic interpretation. With a probability of 70.5% the thread is from the turn of the 13th and 14th centuries (Ua-53815, 691 ± 29 BP, 1260-1320 and 1350-1390 calAD, probability 95.4%).

In the 1950s Agnes Geijer (1954, 296; 1994, 141) dated the topmost silk cover of the skull relic to the end of the 13th century. She analysed the weaving technique and the style of the depiction of mythological characters in the Chinese damask. Again, the radiocarbon dating result of the silk was in harmony with Geijer's conclusions: with a probability of 82.3% the dating covers the period 1220-1310 calAD (Ua-39385, 712 ± 34 BP, 1220-1310 and 1360-1390 calAD, probability 95.4%).

Based on textile research and iconographic analysis, the skull relic should be dated to the end of the 13th century or the first half of the 14th century. With the aid of radiocarbon dating the age estimations can be refined. There are some materials in the skull relic which are younger than the silk in the Chinese damask. These include linen in the two pieces of cloth between the skull structure and the fabric covers. The dating of the linen is 1290-1410 calAD (Ua-42604, 604 ± 30 BP; Ua-55438, 609 ± 26 BP; probability 95.4%). Another young material is the linen in the thread closing one of the bone packages (1290-1410 calAD; Ua-42105, 595 ± 30 BP, probability 95.4%). As the textiles and the thread are inside the reliquary, the skull relic could not have existed before 1290. The assembling of the skull relic probably took place around the middle of the 14th century, which is also indicated by the radiocarbon dating of the silk threads used in closing the silk covers. The dates for both, 1280-1330 and 1340-1400 calAD, lend a slight emphasis to the younger time span (a white silk thread for the red silk cover: Ua-54642, 640 ± 29 BP; a beige silk thread for the beige silk cover: Ua-54643, 648 ± 29 BP; probability for both 95.4%).

The age estimation for the skull assemblage is complicated by the radiocarbon dating of other textiles. Green silk braid has been applied to the front and sides of the skull relic, most of which is hidden by the textile covers (Fig. 5). Samples from two different locations of the braid were extracted for radiocarbon dating. According to the first sample, taken in 2011, the silk was dated to 1310-1350 and 1390-1450 calAD with an emphasis on the more recent period (Ua-42095, 527 ± 30 BP; probability 95.4%). However, the result makes the silk in the braid distinctly younger than any other material in the skull relic, although there are no visible traces of the braid being added later to the artefact. To explore this discrepancy further, another

sample of the braid was taken and analysed in 2017. The result, 1290–1400 calAD, corresponds with the dating of the youngest materials in the skull relic (Ua-55436, 614 ± 26 BP, probability 95.4%). It is difficult to explain the difference in the two dating results, but at least the case proves the benefits of resampling. Ultimately, however, there is no reason to doubt the date of the assembling of the skull relic. It took place around the mid-14th century.

The bones of the skull structure

There were nineteen linen pouches with bones in the skull construction and a few pieces of linen cloth, which were probably the remains of emptied bone packages. Most packages contained only one bone or a fragment, while five had several fragments. For example, one package (#7) contained over forty small pieces of bone (the bone fragments and their details are presented in Table 1).

A macroscopic osteological analysis of the bones was undertaken in 2016. The goals of the analysis were to identify the bones, determine whether they were human or non-human, estimate the sex and age of individuals represented in the relic, and identify whether the bone fragments could be associated with each other. Potential modifications, pathological changes, and taphonomic damage were also documented.

Bone fragments were divided into three groups: cranial bones; post-cranial bones; and unidentified bones. The post-cranial bones include all the identified bones that were not from a cranium or mandible, while unidentified bones include all the fragments that could not be identified as human or non-human bone, or as a specific bone.

Cranial bones

Six of the packages include a cranial bone or fragments of cranial bones. One package comprised a tooth (Table 1). The major bones consist of a mandible (#2), two parietal bones (#6, 9), and an occipital bone (#8). These bones also form the frame of the entire relic, and they were placed in their correct anatomical positions. Two cranial fragments (#10, 15) were also identified, but no further identifications are possible.

The mandible is complete and well preserved. Kajava reports a postmortem fracture between the second premolar and first molar on the left in the radiograph. This fracture is still visible, although it is now adhered. This adhering may have been done in the 1940s when the mandible was taken to

Uppsala for examination. No teeth are present except for two broken tooth roots. The right first molar root is still in its socket but the other, possibly the left second premolar root, is loose and cannot be refitted in its socket, possibly because of the reconstructive adhering. All the teeth except the third molars were probably present at the time of death, since no healing is observed in the alveolar bone. Based on Kajava's (1932, 342) report on the radiographs, the third molars had never formed.

There are no macroscopic methods that can estimate the age at death from a mandible lacking teeth. However, there are some indicators of relative age. For example, all the teeth except the third molars were present at the time of death, and mandibular condyles show no pathological changes in the joint surface. These observations may indicate that the deceased was young or middle-aged, but not elderly.

Sex can be estimated from the mandible using several traits. The most commonly used trait is the shape of the mental eminence (chin) which, in general, is broader and more protruding in males (Buikstra & Ubelaker 1994). Another characteristic used is the gonial angle, which is the angle between the mandibular body and ramus. The angle tends to be more acute in males than in females (Krogman & Iscan 1986, 192; Williams & Rogers 2006, 731). In the mandible of the skull relic the mental eminence area is quite small, but slightly protruding. This may therefore indicate a female. Furthermore, the angle is neither clearly masculine nor feminine. Because of these ambiguous characteristics two additional mandibular traits were scored, even though their reliability has been debated in previous research (Hill 2000; Kemkes-Grottenthaler et al. 2002). In the relic mandible the ramus is straight, exhibiting no flexure at the level of the occlusal surface of the molars. This generally indicates a female (Loth & Henneberg 1996; Kemkes-Grottenthaler et al. 2002). The mandible shows a slight eversion of the gonial angle, which may be considered a neutral trait, since it is more common for males to exhibit eversion, whereas in females this trait can be anything from slight eversion to inversion (Kemkes-Grottenthaler et al. 2002; Oettlé et al. 2009). The mandible in the skull relic seems to exhibit ambiguous characteristics, but based on these traits it is classified as a possible female (Fig. 6). However, a future DNA analysis may provide more conclusive results.

The two parietal bones, right and left, belong to the same individual. There is a cranial suture between these bones, and the suture lines match perfectly, but the suture is closed from the anterior part and the bones have been broken in two before being placed in separate packages. Kajava (1932)

estimates the age of the individual based on the suture closure. However, suture closures are not used as often in age estimation as it used to be because of findings that have shown wide variation in closure times (HersHKovitz et al. 1997), and we can thus conclude that the individual in question was an adult and more likely to be young or middle-aged than elderly.

Another large bone fragment is the squamous part of the occipital bone. The bone is more weathered than the other cranial bones, although it is the youngest one dated in the relic. A morphological trait commonly used in sex estimation, the nuchal crest, is present on the occipital bone. The crest is an attachment site for muscles and is generally larger in males than in females. In the present bone the crest area is not pronounced and may thus indicate a female, but it is difficult to estimate sex on the grounds of only one trait.

One of the packages contains a small tooth (#18), the size of which suggests it is deciduous, but its root morphology more resembles a permanent tooth. Kajava (1932, 342) identifies the tooth from the radiographs as a permanent premolar, while Ingelmark (1954, 254) reports it as a deciduous canine. The morphology suggests it is indeed a canine, but it is smaller than a normal canine. The tooth is also worn to the degree that the dentin is exposed.

Post-cranial and unidentified bones

Four packages contain a fragment of a post-cranial bone. Three are from the pelvis, specifically from the ilium (#4, 12, 17). One package includes a rib fragment from the left side (#16). Their size suggests these fragments are probably from an adult. The ilium fragment (#17) also exhibits a fused iliac crest, indicating an adult.

Eight packages (#1, 3, 5, 7, 11, 13, 14, 19) include a fragment or several fragments that are unidentifiable. Most are small fragments of compact bone or lack identifiable characteristics in general. A non-human origin of these fragments cannot be excluded based on the macroscopic examination.

Modifications of bone

Most of the bones in the skull relic are fragmentary with broken edges. The bones may have been accidentally or deliberately broken. Many of the edges are rounded, which may suggest they have been constantly handled for quite a long period before being deposited in the reliquary. Most of the

edges are slightly lighter in colour than the surrounding bone, which usually indicates that the breakage happened after death (Galloway et al. 2014, 50).

Two bones exhibit clear tool marks. A fragment of an ilium from package no. 4 has three shallow incision marks on the medial side of the bone. They range from 2 to 25 mm in length. There is no clear indication what the incisions are for, but they are probably related to the preparation of the relic.

The right parietal from package no. 6 has an almost circular perforation through the bone (Fig. 7). The maximum diameter of the perforation is about 13 mm. No signs of healing can be seen on the bone, and the margins are slightly lighter in colour than the surrounding bone. A larger area of breakage is observed on the interior surface of the bone, indicating that the hole was made from the outside. No radiating or other fractures associated with the defect is detectable. The walls of the perforation are vertical but rugged. The outer surface around the perforation displays some slightly polished areas which may indicate the use of a metal tool or wear (Murphy 2003, 213). A round depression has been made next to the perforation. This may be a false start for another perforation.

The timing of the defect can be estimated based on its macroscopic characteristics. However, identifying when the injury or damage occurred can sometimes be difficult or even impossible (Maples 1986; Loe 2009; Galloway et al. 2014). In this case the lack of healing of the margins indicates the perforation was probably done at the time of death (perimortem) or after death (postmortem). The colour of the margins of the perforation and the area around it differ from the colour of the surrounding bone. This colour difference usually indicates postmortem breakage (Galloway et al. 2014, 50). Other characteristics consistent with postmortem breakage are rough and uneven margins of the perforation and the absence of other fractures. Yet the bone has not shattered in any of the ways commonly observed in postmortem fractures (Galloway et al. 2014, 50). Based on these traits, and without further details on the taphonomic processes involved, the perforation seems more similar to a postmortem defect than a perimortem one.

Several methods have been suggested in the literature for making perforations in the cranial bones. These commonly involve the trepanation of living individuals. These methods include scraping, grooving, drilling or boring, chiselling, and sawing (Lisowski 1967, 661; Kirkup 2003, 290ff.). The right parietal in the skull relic shows no sign of scraping, grooving, or cutting, and the shape of the hole and the margins do not indicate drilling. The margins of the perforation are uneven and may evince some sort of gouging. There is a small polished area around the hole that may reflect

the use of a metal tool such as a gouge (Murphy 2003, 213). However, the depression next to the perforation does not appear to have been made by gouging, but rather by the force of pressure.

Several interpretations of the perforation in the right parietal can be posited. It may be a perimortem trepanation done as a surgical treatment which the patient did not survive. However, considering the characteristics of the perforation, it is more likely to be a postmortem defect made for religious or ritual purposes (Lisowski 1967, 659; Murphy 2003), or to hang or attach the bone to a surface for other reasons. Both healed and unhealed trepanations in archaeological materials are commonly seen on the left parietal or frontal (Lisowski 1967, 659; Roberts & Manchester 2005, 126). In this case the perforation is on the right parietal, which, with the lack of traumatic lesions on the parietals, may thus support the idea of a postmortem defect.

Associations between the bones

It is important to evaluate whether these bones come from the same individual or if multiple individuals are involved. Only two of the bones (#6, 9) can be refitted together and thus can be said to originate from the same individual. Other associations between the bone fragments are best addressed with radiocarbon dating, but in future DNA analysis may help to establish further associations between fragments as well. By April 2017 bones in fifteen of the nineteen packages had been dated (Table 1). The calibrated dates range from 550 BC to 1220 AD, but there are clearly seven clusters with similar dates: 550–50 BC, 180–1 BC, 50 BC–90 AD, 50–240, 240–430, 660–900 and 1040–1220. In the case of three packages (#7, 5, 13), which include several bone fragments, the sample for scientific dating was extracted from only one fragment, and it thus remains unknown whether all the pieces in the packages are contemporary. Nor can it be concluded based on the macroscopic examination if the contemporaneous bones belonged to the same individual.

The oldest dates are mostly from unidentified fragments (#1, 5, 7, 10, 13, 14), except one ilium fragment (#12) that coincides with the cluster dated to 50 BC–90 AD and a rib fragment (#16) in the cluster dated to 50–240. The mandible (#2) has been dated to 250–300 or 320–430. These dates coincide with the dates from package nos. 4 and 3. The parietals (#6, 9) belong to the same date cluster (660–900), with one unidentified cranial fragment (#15). The occipital bone (#8) is the youngest fragment, dating to 1040–1220, and it remains the only one dated to the period when Saints Eric and Henry lived.

The material complexity of medieval relics

The re-examination of the skull relic at Turku Cathedral reveals what intricate objects medieval reliquaries and relics are. The study of this complicated item not only refutes and revises old interpretations, it also raises new issues and points of interest for further scholarship on medieval relics and their position in the cult. An unavoidable realisation is that the understanding of relics should not focus solely on the moment when they were acquired and deposited in reliquaries. Instead, an investigation must consider the long history of material changes that the objects have experienced. A holistic approach to the materiality of the skull relic of Turku requires the integration of different strains of information. It involves the re-evaluation of previous iconographical and historical reasoning, as well as the acquisition of new scientific data on the age of different elements, a macroscopic osteological analyses of the bones, and the documentation of the physical construction of the reliquary.

The question of the authenticity of medieval relics, or rather their correct identification, was a driving force in Rinne's and Nordman's work, but had a particularly modern emphasis. This was manifested in Rinne's pioneering application of scientific methods of anatomical examination to the bones. However, the development of the methodology and the introduction of other scientific methods like radiocarbon dating also undermine his and Nordman's assumptions and conclusions. Their interpretations rested on historical and iconographic analyses and were supported by anatomical inferences. They assumed that the skull relic of Turku must be a pivotal saint for the cathedral and the history of the diocese. The holy man had to be one of the two major saints associated with the history of Finland, St Henry or St Eric. However, the new scientific data supports neither Rinne's nor Nordman's identifications.

Rinne and Nordman considered the mandible the core of the skull relic. The assumption functioned well as the basis for their subsequent theories, since the mandible was lacking both from the presumed skull of St Henry at Turku Cathedral and the skull of St Eric at Uppsala Cathedral. This assumption, however, must be questioned, because the mandible is a loose bone and as such inferior to cranial bones sheltering the brain, which, beside the heart, was considered the most vital organ in late medieval thought (Cohen 2013, 68-71). There are mandible relics (for example, that of St Anthony of Padua in Italy), but skull relics constructed on a mandible were not known to the authors.

Ingelmark determined the mandible to be female and the new osteological analysis supports his view. Nordman sought to avoid the problem

posed by the wrong sex by explaining that the mandible was considered St Eric's relic when the skull relic was compiled. The radiocarbon dating result, however, has revealed that the mandible was already about 800 years old when it was added as part of the skull relic. It is unlikely that such a mandible was available in Uppsala. Altogether, the age of the mandible refutes assumptions of its belonging either to St Eric or St Henry.

The two parietal bones from the same skull form the core of the skull relic. Of the other two central bones, the occipital and the frontal, the latter is missing. If the crania in Turku and Uppsala Cathedrals belong to St Henry and St Eric, none of these bones belong to them, because the skulls are – apart from the mandibles – complete. Hence, there is no physical connection between the skull relic at Turku Cathedral and the two Nordic saints.

In the medieval cult of relics skull relics had a particularly strong link with St Ursula and the 11,000 virgins. The most abundant concentration of skull relics is at the centre of the cult, the Basilica of St Ursula in Cologne. When a Roman cemetery, providing masses of ancient human remains, was discovered there in 1106, the cult spread quickly across Europe (Montgomery 2016, 19, 24f.). By the end of the Middle Ages relics of the 11,000 virgins were found not only in Germany, Belgium, and the Netherlands (e.g. Van Strydonck et al. 2006; Sorber et al. 2010; de Kruijf 2011; Becker-Huberti & Beikircher 2012), but they found their way further north and east to Denmark (e.g. the Cistercian Abbey of Esrom and Lund Cathedral; Montgomery 2010, 29; Karlsson 2015, 482ff.) and Poland (e.g. the Cistercian Abbey of Łąd; Mrozowski & Nowiński 2015, 64–87; Nowiński 2016, 208–57). They are also mentioned in the inventory of relics in the main cathedral of the archdiocese of Sweden, Uppsala, around 1344 (SDHK 4953).

St Ursula and the 11,000 virgins were also important in the medieval diocese of Turku, in whose calendar of saints their feast day appeared early. The significance was emphasised particularly at the beginning of the 15th century, when the day was raised to the highest rank of ecclesiastical feast, *totum duplex* (Malin 1925, 86, 168f.). A chapel and associated altar for the 11,000 virgins were founded in Turku Cathedral in 1455 (Rinne 1948, 82).

Although the interpretation of the skull relic as St Ursula's or one of the 11,000 virgins seems attractive, it has significant problems. The altar for the 11,000 virgins at Turku Cathedral was founded in 1455, but the skull relic had already been assembled a hundred years earlier, approximately in the second quarter of the 14th century. Additionally, there are two other relics in the relic assemblage of Turku Cathedral, which, because of their dating

and the other preserved authentica (St Benedicta), are probably related to the founding of the altar.

Most skull relics related to the cult of the 11,000 virgins are complete crania with a silk wrapping. Occasionally, the pieces of broken crania have been adhered to each other, but constructions with separate linen pouches containing bones and sewn together are rare. An example of a construction similar to the skull relic at Turku Cathedral is among the skull relics in the altar complex of the 11,000 virgins at Łąd Abbey, Poland. It is probable that other similar constructions exist, but they are visible only if the wrapping is missing or partly dismantled. Such a time-consuming solution was probably used only if the bones originated from different skulls and there was no other way to join them together.

In almost all the skull relics of the 11,000 virgins part of the frontal bone remains exposed. In the skull relic at Turku Cathedral, however, there is no frontal bone, and it is possible to see inside the construction. Like part of the silk wrapping, the frontal bone was probably taken as a memento. Indeed, the empty linen packages in front of the skull relic point to souvenir hunting. The example in Łąd Abbey points to the possibility that unwrapped pieces of bone were attached to linen pouches by drilling the bones and binding them to the fabric with a thread.

Perforations are a relatively common feature of the skull relics related to the cult of the 11,000 virgins. At St Quinten Cathedral in Hasselt in Belgium there is a postmortem perforation on the right parietal of a skull relic (Fanny van Cleven, KIK-IRPA, pers. comm.; inv. no. 39; <http://balat.kikirpa.be/object/62284>). Further examples of perforations are in the skull relics of the Basilica of St Ursula in Cologne and the Abbey Church of Łąd in Poland. The perforations were probably considered proof of martyrdom and thus exposing them was appropriate. In the skull relic at Turku Cathedral the two innermost wrappings reveal the hole in the parietal bone, but the outermost silk fabric covers it. Was this an attempt to hide the contradiction between the perforation, which may have been thought to be the result of a fatal strike, and the embroidery depicting a decapitation? However it may be, perforations are not an exclusive feature of the skull relics of the 11,000 virgins. For example, there is the skull of a count of Toulouse with two perforations found in a sarcophagus outside Toulouse Cathedral (Crubézy & Murail 1996, 78).

As far as the wrapping is concerned, thin metal plates or parchment flowers may be sewn on the medieval silk wrappings of the skull relics associated with the cult of the 11,000 virgins. Occasionally, there are also embroideries

in the skull relics of the 11,000 virgins, but such narrative representations as the one on the skull relic at Turku Cathedral seem to be lacking.

In sum, the skull relic at Turku Cathedral includes features in common with the skull relics related to the cult of the 11,000 virgins, but there are also significant differences. They may be explained by the adaptation of the cult's skull relic tradition to local circumstances. However, the most important problem is the date of some bones in the skull relic. According to the radiocarbon dating they are older than the Roman graveyards in Cologne. Furthermore, most of the first Roman burials were cremations (Euskirchen 2014, 29), and there are no scorch marks on the bones of the skull relic. Keeping this in mind, the skull relic at Turku Cathedral may represent some other medieval cult involving the wrapping of skull relics in textiles (cf. Van Strydonck et al. 2006, 152; Stracke-Sporbeck 2016, 103f.).

The osteological analysis of the skull relic shows that not all the bones in the assemblage are cranial, a feature also encountered in other reliquaries shaped like a body part (Bynum & Gerson 1997). In the skull relic the major cranial bones, including the parietals, the occipital, and the mandible, give shape to the skull, and they are in their correct anatomical locations. Three fragments from the pelvis are used, probably because they are flat bones similar to the cranial bones. The rest of the bone packages mostly fill the empty spaces of the actual skull structure. The major bones are human, but the non-human origin of the small fragments cannot be excluded based on the macroscopic examination.

The radiocarbon dates of the individual elements in the reliquary, including bones, textiles, and threads, testify to a wide chronological range. The dates of the bones range from 550 BC to 1220 AD with seven clusters. While the oldest bones may be as old as the 6th century BC, the dates of the textiles and threads reveal that the skull relic was assembled around the mid-14th century.

The structural study of the skull relic of Turku exposes how intricate the relationship between relics and reliquaries was. The bone fragments were wrapped in linen pouches stitched with thread, and then these small pouches were deposited inside layers of cloth. It is apparent that the function of a reliquary was more than just to protect the bones: it organised the holy remains in a form recognisable as a human skull.

This new study of the skull relic in Turku reveals the complexity of medieval objects of devotion and the power of scientific analysis to access their material history. The combination of radiocarbon dating with a macroscopic osteological study has revealed that both Rinne and Nordman were incor-

rect in their identifications of the skull relic as St Henry or St Eric. Although the identity of the relic's saint remains elusive, the interdisciplinary and detailed study of the materiality of the skull relic discloses a number of other material phenomena relevant for understanding the use of medieval devotional objects as part of the cult of relics.

* * *

AKI ARPONEN is PhD Student, University of Turku. E-mail: aki.v.arponen@utu.fi

VISA IMMONEN is Professor of Archaeology, University of Turku. E-mail: visa.immonen@utu.fi

HELI MAIJANEN is University Lecturer of Archaeology, University of Oulu, Finland. E-mail: heli.maijanen@oulu.fi

Bibliography

Angenendt, Arnold

2007 *Heilige und Reliquien. Die Geschichte ihres Kultes vom frühen Christentum bis zur Gegenwart*. Hambrug: Nikol, 2. Auflage.

Arponen, Aki

2015 The Medieval Skull Relic of Turku Cathedral. Preliminary Results of Analyses. – *Mirator* 16(1), 102–116.

Aymard, Orianne

2014 *When a Goddess Dies. Worshipping Ma Anandamayi after Her Death*. Oxford: Oxford University Press.

Bagnoli, Martina, Holger A. Klein, C. Griffith Mann & James Robinson (eds)

2011 *Treasures of Heaven. Saints Relics and Devotion in Medieval Europe*. London: British Museum.

Bartlett, Robert

2013 *Why Can the Dead Do Such Great Things? Saints and Worshippers from the Martyrs to the Reformation*. Princeton & Oxford: Princeton University Press.

Becker-Huberti, Manfred & Konrad Beikircher

2012 *Kölner Reliquien. Heilige Knöchelchen schräg betrachtet*. Köln: J. P. Bachem Verlag.

Braun, Joseph

1940 *Die Reliquiare der christlichen Kultes und ihre Entwicklung*. Freiburg im Breisgau.

Buikstra, Jane E. & Douglas H. Ubelaker

1994 *Standards for Data Collection from Human Skeletal Remains*. Fayetteville: Arkansas Archeological Survey.

Bynum, Caroline Walker

1995 *The Resurrection of the Body in Western Christianity, 200–1336*. New York: Zone.

2002 Violent Imagery in Late Medieval Piety. – *GHI Bulletin* 30, 3–36.

2011 *Christian Materiality: An Essay on Religion in Late Medieval Europe*. New York: Zone Books.

Bynum, Caroline Walker & Paula Gerson

1997 Body-Part Reliquaries and Body Parts in the Middle Ages. – *Gesta* 36(1), 3–7.

Cohen, Ester

2013 The Meaning of the Head in High Medieval Culture. – Catrien Santing, Barbara Baert & Anita Traninger (eds), *Disembodied Heads in Medieval and Early Modern Culture*. (Intersections. Interdisciplinary Studies in Early Modern Culture, 28). Leiden: Brill.

Crubézy, É. & P. Murail

1996 Combien étaient-ils? Le comte de l'An Mil. *Revue Aquitania*, supplément 8, 1996, 76–82.

Euskirchen, Marion

2014 Tod am Eigelstein. Bestattungsbräuche der Römer. – Mario Kramp & Marcus Trier (eds), *Drunter und drüber der Eigelstein*. *Schauplatz Kölner Geschichte* 2, 27–31.

Galloway, Alison & Lauren Zephro & Vicki L. Wedel

2014 Diagnostic Criteria for the Determination of Timing and Fracture Mechanism. – Vicki L. Wedel & Alison Galloway (eds), *Broken Bones. Anthropological Analysis of Blunt Force Trauma*, 47–58. Springfield, IL: Charles C. Thomas.

Gardberg, C. J. & Simo Heininen & P. O. Welin

2000 *Kansallispyhäkkö. Turun tuomiokirkko 1300–2000*. Helsinki: Tammi.

Geary, Patrick

1986 Sacred Commodities. The Circulation of Medieval Relics. – Arjun Appadurai (ed.), *The Social Life of Things. Commodities in Cultural Perspective*, 169–91. Cambridge: Cambridge University Press.

George, Philippe

2013 *Reliques, le quatrième pouvoir. Pour une histoire des reliques en Europe, du Moyen Âge à nos jours*. Nice: Les Éditions Romaines.

Geijer, Agnes

1954 Textilierna i Sankt Eriks skrin. – Bengt Thordeman (ed.), *Erik den Helige. Historia – Kult – Reliker*, 289–302. Stockholm: Nordisk rotogravyr.

1994 *Ur textilkonstens historia*. Stockholm: Tidens förlag.

Hahn, Cynthia

2017 *The Reliquary Effect. Enshrining the Sacred Object*. London: Reaktion.

Heikkilä, Tuomas

2005 *Pyhän Henrikin Legenda*. Helsinki: Suomalaisen Kirjallisuuden Seura.

**Hershkovitz, Israel & Bruce Latimer & Olivier Dutour & Lyman M. Jel-
lema & Susanne Wish-Baratz & Christine Rothschild & Bruce M.
Rothschild**

1997 Why Do We Fail in Aging the Skull from the Sagittal Suture? – *American Journal of Physical Anthropology* 103(3), 392–99.

Hill, Cheryl A.

2000 Technical Note: Evaluating Mandibular Ramus Flexure as a Morphological Indicator of Sex. – *American Journal of Physical Anthropology* 111, 573–77.

Hooper, Steven

2014 Bodies, Artefacts and Images. A Cross-cultural Theory of Relics. – James Robinson, Lloyd de Beer & Anna Harnden (eds), *Matter of Faith. An Interdisciplinary Study of Relics and Relic Veneration*, 190–99. London: British Museum.

Houston, Mary G.

1996 *Medieval Costume in England and France. The 13th, 14th and 15th Centuries*. New York: Dover Publications.

Ingelmark, Bo E.

1954 Skelettdelarna i Erik den Heliges relikskrin. – Bengt Thordeman (ed.), *Erik den Helige. Historia – Kult – Reliker*, 233–68. Stockholm: Nordisk rotogravyr.

Kajava, Yrjö

1932 Kallolaitteen luusto. – Juhani Rinne, *Pyhä Henrik. Piispa ja marttyyri*, 336–45. Helsinki: Otava.

Karlsson, Mattias

2015 *Konstruktionen av det heliga. Altarna i det medeltida Lunds stift*. Skånsk senmedeltid och renässans 23. Lund: Vetenskaps-societeten i Lund.

Karttila, Mira

2014 The Cap of St Birgitta of Sweden. Research and Conservation of

Medieval Reliquary. – Sanna Lipkin & Krista Vajanto (eds), *Focus on Archaeological Textiles. Multidisciplinary Approaches*, 10–25. Helsinki: Archaeological Society of Finland.

Kemkes-Grottenthaler, Ariane & F. Löbig & Frauke Stock

2002 Mandibular Ramus Flexure and Gonial Eversion as Morphologic Indicators of Sex. – *HOMO* 53(2), 97–111.

Kirkup, John

2003 The Evolution of Cranial Saws and Related Instruments. – Robert Arnott, Stanley Finger, Chris Smith, Robert Arnott, Stanley Finger & Chris Smith (eds), *Trepanation. History, Discovery, Theory*, 289–304. Lisse: Swets & Zeitlinger.

Krogman, Wilton Marion & Mehmet Yaşar İşcan

1986 *The Human Skeleton in Forensic Medicine*. Springfield, IL: Charles C. Thomas.

de Kruijf, Anique C.

2011 *Miraculeus bewaard. Middeleeuwse Utrechtse relieken op reis. De schat van de oud-katholieke Gertrudiskathedraal*. Zutphen: Uitgeversmaatschappij WalburgPers.

Lindman, A.

1869 *Bidrag till Åbo stads historia. Första häftet. Anteckningar om Åbo Domkyrka och dess fornminnen*. Åbo: Frenckellska boktryckeriet.

Lisowski, F. P.

1967 Prehistoric and Early Historic Trepanation. – Don Brothwell & A. T. Sandison (eds), *Diseases in Antiquity*, 651–72. Springfield, IL: Charles C. Thomas.

Loe, Louise

2009 Perimortem Trauma. – Soren Blau & Douglas Ubelaker (eds), *Handbook of Forensic Anthropology and Archaeology*, 263–83. Walnut Creek, CA: Left Coast Press.

Loth, Susan R. & Maciej Henneberg

1996 Mandibular Ramus Flexure. A New Morphologic Indicator of Sexual Dimorphism in the Human Skeleton. – *American Journal of Physical Anthropology* 99, 473–85.

Malin, Aarno

1925 *Der Heiligenkalender Finnlands. Seine Zusammensetzung und Entwicklung*. Helsinki: Suomen Kirkkohistoriallinen Seura.

Maples, W. R.

1986 Trauma Analysis by the Forensic Anthropologist. – K. J. Reichs (ed.), *Forensic Osteology. Advances in the Identification of Human Remains*, 218–28. Springfield, IL: Charles C. Thomas.

Meri, Josef W.

2010 Relics of Piety and Power in Medieval Islam. – *Past Present* 206, 97–120.

Miller, Patricia Cox

2009 *The Corporeal Imagination. Signifying the Holy in Late Ancient Christianity*. Philadelphia: University of Pennsylvania Press.

Montgomery, Scott B.

2010 *St Ursula and the Eleven Thousand Virgins of Cologne. Relics, Reliquaries and the Visual Culture of Group Sanctity in Late Medieval Europe*. Bern: Peter Lang.

Mrozowski, Przemysław & Janusz Nowiński.

2015 Tkanina herbowa z Łądu i zespół trzynastowiecznych tkanin dekorujących relikwie Undecim Milium Virginum w ołtarzu św. Urszuli w Łądzie. – Janusz Nowiński (ed.), *Lenda medii aevi. Średniowieczne zabytki dawnego opactwa w Łądzie – nowe odkrycia, najnowsze badania*, 64–87. Łąd-Poznań-Warszawa: Towarzystwo Naukowe Franciszka Salezego.

Murphy, Eileen M.

2003 Trepanations and Perforated Crania from Iron Age South Siberia. An Exercise in Differential Diagnosis. – Robert Arnott, Stanley Finger, Chris Smith, Robert Arnott, Stanley Finger & Chris Smith (eds), *Trepanation. History, Discovery, Theory*, 209–221. Lisse: Swets & Zeitlinger.

Nafte, Myriam

2015 Institutional Bodies. Spatial Agency and the Dead. – *History and Anthropology* 26(2), 206–33.

Newton, Stella Mary

2002 *Fashion in the Age of the Black Prince. A Study of the Years 1340–1365*. Woodbridge & Rochester: Boydell.

Nordman, Carl Axel

1954 En relik av Erik den helige i Åbo domkyrka. – Bengt Thordeman (ed.), *Erik den Helige. Historia – Kult – Reliker*, 303–20. Stockholm: Nordisk rotogravyr.

Nowiński, Janusz

2016 *Ars cisterciensis. Kościół cysterski w średniowieczu - wyposażenie i wystrój*. Warszawa: New Media Concept.

Oettlé, Anna C. & Ethersia Pretorius & Maryna Steyn

2009 Geometric Morphometric Analysis of the Use of Mandibular Gonial Eversion in Sex Determination. – *HOMO* 60, 29–43.

Pykkänen, Riitta

1976 *Ars sacra / ornamenta sancta cathedralis aboensis*. Turku: Turun evankelis-luterilainen seurakunta & Turun taidemuseo.

Rinne, Juhani

1932 *Pyhä Henrik. Piispa ja marttyyri*. Helsinki: Otava.

1948 *Turun tuomiokirkko keskiaikana. II Alttarit ja kirkolliset toimitukset*. Turku: Turun tuomiokirkon isännistö.

Riska, Tove

1987 Keskiajan interiööriin liittyvä esineistö ja taidekäsityö. – Salme Sarajas-Korte (ed.), *Ars. Suomen taide 1*, 226–65. Espoo: Weilin + Göös.

Roberts, Charlotte & Keith Manchester

2005 *The Archaeology of Disease*. Ithaca, NY: Cornell University Press.

Robinson, James & Lloyd de Beer & Anna Harnden (eds)

2014 *Matter of Faith. An Interdisciplinary Study of Relics and Relic Veneration*. London: British Museum.

Scott, Margaret

2007 *Medieval Dress & Fashion*. London: British Library.

Sorber, Frieda & Fanny Van Cleven & Shiren Van Eenhoeghe

2010 *Schedelreliëken van Herkenrode*. Brussel: Koninklijk Instituut voor het Kunstpatrimonium (KIK).

Stracke-Sporbeck, Gudrun

2016 Et aliorum plurimorum sanctorum reliquie. Textile Ausstattung und Reliquienfassung im Stift St. Gereon. – Margrit Jüsten-Mertens (ed.), Die kostbaren Hüllen der Heiligen – Textile Schätze aus Kölner Reliquienschreinen. Neue Funde und Forschungen. *Colonia Romanica. Jahrbuch des Fördervereins Romanische Kirchen Köln e.V.* XXXI, 97–112.

Strong, John S.

2007 *Relics of the Buddha*. Delhi: Motilal Banarsidass.

Taavitsainen, Jussi-Pekka

2011 Interdisciplinary Perspectives on the Medieval Relics and Reliquaries of Turku Cathedral, Finland. – *Material Religion* 7(3), 447–50.

Taavitsainen, Jussi-Pekka & Markku J. Oinonen & Göran Possnert

2015 The Turku Cathedral Relics Revisited and Anonymous Relics Dated to the Eleventh and Twelfth Centuries. – *Mirator* 16(2), 308–22.

Van Strydonck, Mark & Anton Eryvynck & Marit Vandenbruaene & Mathieu Boudin

2006 *Relieken. Echt of vals?* Leuven: Davidsfonds.

Vanden Berghe, Ina

2016 *Analysis report. Relics from Turku cathedral*. KIK-IRPA file number 2016.13023.

Ward, Benedicta

2010 Relics and the Medieval Mind. – *International Journal for the Study of the Christian Church* 10(4), 274–86.

Williams, Brenda A. & Tracy L. Rogers

2006 Evaluating the Accuracy and Precision of Cranial Morphological Traits for Sex Determination. – *Journal of Forensic Science* 51, 729–35.

Internet Sources

SDHK

Svenskt Diplomatoriums huvudkartotek över medeltidsbrev. <<https://sok.riksarkivet.se/sdhk>>, accessed 30 October 2017.

Appendix

Fig. 1. The anonymous skull relic of Turku Cathedral before the scientific examination in 2011. The length of the object is 19.2 cm. Photo: Aki Arponen.



Fig. 2. The structure inside the textile reliquary. The photo was taken during the scientific examination in 2011. Photo: Aki Arponen.



Fig. 3. The depiction of a martyrdom embroidered on the silk wrapping. Photo: Aki Arponen.



Fig. 4. The knight with a surcote which went out of fashion after the mid-14th century. Photo: Aki Arponen.



Fig. 5. The green silk braid is visible due to the collectors of mementos who have cut off pieces of the Chinese silk damask. Photo: Aki Arponen.

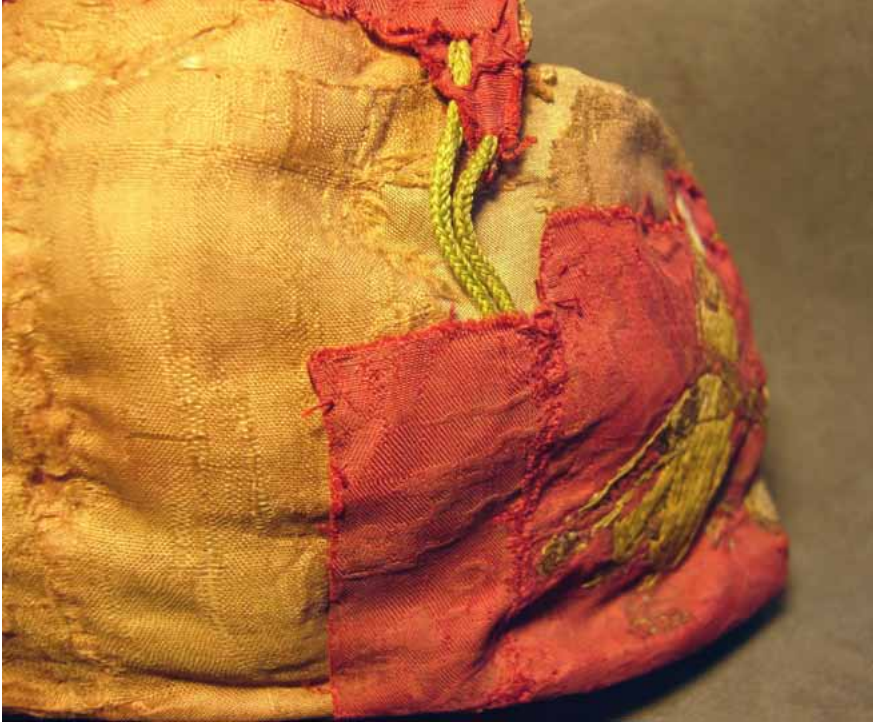


Fig. 6. The mandible in the skull relic (package 2). Photo: Aki Arponen.



Fig 7. The right parietal (package 6) with a perforation c. 13 mm in diameter and a round depression. Photo: Aki Arponen.



Table 1. Bone packages inside the Turku Cathedral skull relic, their identification, and the radiocarbon dates of the bones. In the table, ‘texture’ refers to the major bone type (outer compact, cortical, bone or inner spongy, trabecular, bone) present in the fragments, while ‘preservation’ is evaluated if bones are more complete (from partial to complete). The radiocarbon datings were done in Ångström Laboratory at Uppsala University. The marine reservoir effect on the radiocarbon dating results of the relic bones in the Turku Cathedral relic assemblage has been discussed in Taavitsainen, Oinonen & Possnert 2015 (NB. In the article in question, the radiocarbon dating result of the bone in the package 8 is incorrect).

- ¹ Probability 94.1%.
² Probability 93.7%.
³ Probability 94.4%.
⁴ Probability 88.6%.

Package	Identification of the bone	Number of bones/ fragments in the package	Maximum size in mm	Texture/ Preservation	Colour	Laboratory number for the radiocarbon dating	Radiocarbon dating result of the bone (BP)	Calibrated radiocarbon datings of the bone (probability 95.4%)
1	Unidentified fragments	3	20.3	Mainly trabecular	Yellowish brown	Ua-53812	2073±29	180–1 calBC
2	Mandible	1	–	Complete	Light brown	Ua-44315	1675±30	250–300 and 320–430 calAD
3	Unidentified fragment	1	22.8	Mainly cortical	Yellowish	Ua-42098	1692±30	250–420 calAD
4	Ilium fragment	1	59.0	Cortical/trabecular	Yellowish	Ua-42100	1717±30	240–400 calAD
5	Unidentified fragments	Over 30	33.9	Mainly cortical	Yellowish brown	Ua-42101	1973±33	50 calBC–90 calAD ¹
6	Right parietal	1	132.5	Almost complete	Yellowish brown	Ua-44318	1268±30	660–820 calAD ²
7	Unidentified fragments	43	22.9	Cortical	Brownish grey	Ua-50738	2264±83	550–50 calBC
8	Occipital	Over 8	97.5	Partial	Yellowish	Ua-42102	883±31	1040–1220 calAD
9	Left parietal	1	122.0	Almost complete	Yellowish brown	Ua-50739	1314±30	650–780 calAD
10	Unidentified cranial fragment	1	21.5	Cortical/diploë	Yellowish brown	Ua-50740	1885±31	50–220 calAD
11	Unidentified tubular bone fragment	1	29.6	Cortical	Light yellow	not dated		
12	Ilium fragment	1	25.9	Cortical/trabecular	Yellowish	Ua-50741	1980±30	50 calBC–80 calAD
13	Unidentified fragments	Over 5	24.9	Mostly cortical	Brownish	Ua-42103	1990±31	50 calBC–80 calAD
14	Unidentified fragment	1	40.3	Cortical/trabecular	Brownish grey	Ua-42104	1896±30	50–220 calAD ³
15	Unidentified cranial fragment	1	27.0	Cortical/diploë	Brownish	Ua-42107	1189±30	760–900 calAD ⁴
16	Rib fragment	1	30.1	Cortical/trabecular	Yellowish	Ua-50742	1851±30	80–240 calAD
17	Ilium fragment	1	58.4	Cortical/trabecular	Yellowish	not dated		
18	Tooth	1	16.3	Complete	–	not dated		
19	Unidentified fragment	1	14.2	Mainly cortical	Yellowish brown	not dated		

